

Pleural Ultrasonography

Subani Chandra* and Mangala Narasimhan

The Division of Pulmonary, Sleep and Critical Care Medicine, Long Island Jewish Medical Centre, Albert Einstein College of Medicine, New Hyde Park, NY 11040, USA

Abstract: Pleural pathology is frequently found in patients admitted to the intensive care unit (ICU). Ultrasonography provides prompt, accurate, and safe diagnosis of pleural diseases at the bedside and guides intervention when necessary. Ultrasonography is an indispensable tool for any intensivist. This article reviews the basic concepts of pleural ultrasonography and its clinical applications in the ICU.

Keywords: Ultrasound, A lines, effusion, pneumothorax, lung sliding, thoracentesis.

THE PHYSICS OF PLEUROPULMONARY ULTRASONOGRAPHY

The principles of pleuropulmonary ultrasonography are the same as those for any other organ. Every tissue transmits, reflects, refracts, scatters, attenuates, and absorbs ultrasound waves variably making the visualization of tissue interfaces possible. For instance, bony tissue almost completely absorbs ultrasound waves, thus casting an acoustic shadow. On the other hand, air completely reflects ultrasound waves, making the visualization of air-filled structures such as lung, impossible.

Bone shadowing artifact from the ribs and air reflection artifact from aerated lung form the background of pleuropulmonary ultrasonography. As this article will elucidate, a systematic study of such artifacts yields invaluable information about the underlying lung and pleura and routinely out-performs other diagnostic modalities including computed tomography (CT).

THE SETUP

As with any process, proper equipment set up is important to maximize yield and increase accuracy. Transducer design and frequency influence image acquisition. In general, as the frequency increases, the resolution improves but the depth of penetration decreases. A standard 3.5 – 5 MHz microconvex transducer works well for pleuropulmonary ultrasound. It has a small ‘footprint’ and fits easily in the intercostal spaces even in thin individuals. A probe with a higher frequency (in the range of 7.5 – 10 MHz) allows for closer examination of the pleural surface. However, it lacks depth of penetration to identify deeper pathology, such as pleural effusions and consolidated lung, reliably.

Any simple, two-dimensional ultrasound machine is adequate for pleuropulmonary ultrasonography since doppler capability is not required. By standard convention, the marker on the screen should always be in the top left corner. Imaging of the pleura and lung always begins in the

longitudinal (cephalo-caudad) plane, with the marker on the transducer cephalad. This implies that the head of the patient is always to the left of the image on the screen.

The operator must adjust depth and gain settings before beginning the examination. We find it helpful to start with higher depth and then zoom in on findings of interest. This way the operator is unlikely to miss any deeper structures. Adjustment of total gain and then near- and far-field gain is important for best image quality. Inappropriate gain can ‘obliterate’ tissue planes and decrease the yield of an ultrasound examination. Finally, a planned and methodical approach helps maximize accuracy of pleuropulmonary ultrasound.

IDENTIFICATION OF USUAL ANATOMIC STRUCTURES

The thorax has three zones for the purposes of an ultrasound examination. The anterior zone is defined medially by the sternum, superiorly by the clavicle, laterally by the anterior axillary line and inferiorly by the diaphragm. The lateral zone lies between the anterior and posterior axillary lines. The posterior zone stretches from the posterior axillary line to the posterior midline [1].

The ribs are a basic and important landmark. They are easy to identify in standard longitudinal scan. The ribs appear as arced structures that cast an acoustic shadow (Fig. 1). Dragging the probe down longitudinally allows the examiner to scroll over the ribs and examine each intercostal space. The moving rib shadows in this maneuver appear like spokes of a rotating wheel.

The diaphragm defines the inferior boundary of the thorax. It helps discriminate intra-thoracic pathology (such as a pleural effusion) from intra-abdominal pathology (e.g. ascites). The diaphragm is most easily visualized in longitudinal scan in the lateral zone. The presence of a pleural effusion makes the diaphragm easier to appreciate. It is a large hyperechoic arced structure that moves with respiration (video 1). Occasionally, the entire arc of the diaphragm may be difficult to see. However, the presence of a ‘curtain sign’ helps in locating the inferior boundary of the thorax. The curtain sign refers to the phenomenon of the lung sweeping down during inspiration over the intra-abdominal organs hiding them from view. In exhalation, the

*Address correspondence to this author at the Division of Pulmonary, Sleep and Critical Care Medicine, The Long Island Jewish Medical Centre, The Albert Einstein College of Medicine, New Hyde Park, NY 11040, USA; Tel: 516-465-5400; Fax: 516-465-5454; E-mail: schandra@nshs.edu

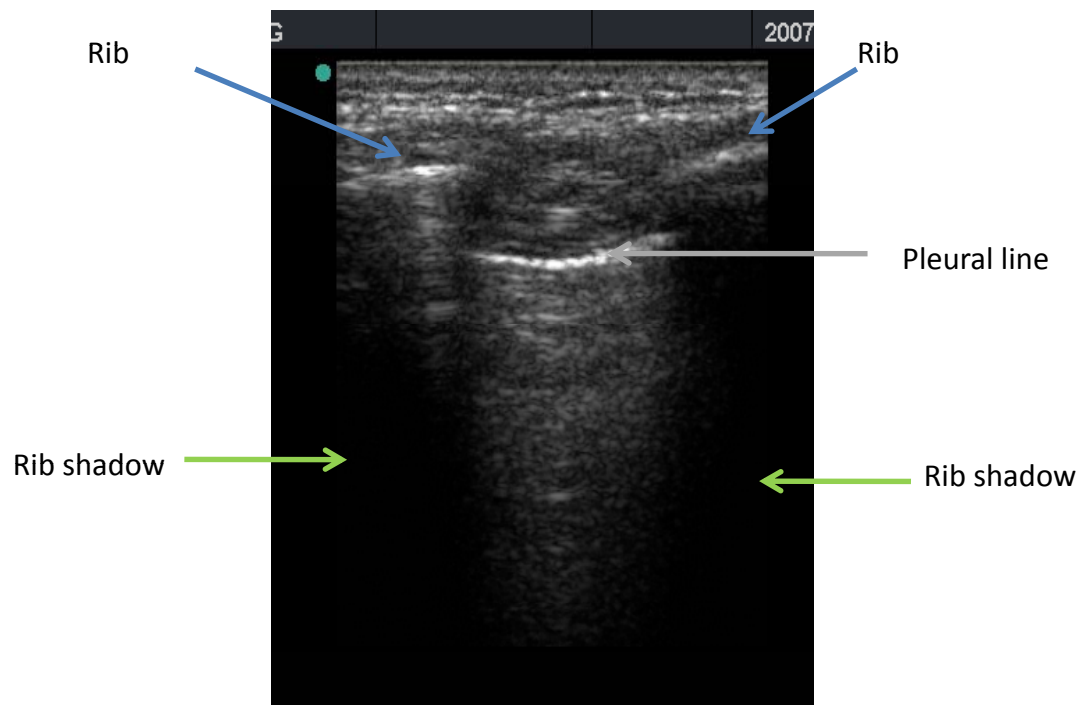


Fig. (1). Ultrasound showing ribs on either side of the pleural line. The ribs cast acoustic shadows. The pleural line is about 0.5cm below the ribs.

lung moves back and the liver or spleen and kidney can once again be seen (video 2).

The normal pleural line is located 0.5 cm below the ribs. It forms the interface between the soft tissues of the chest wall above and the air-reflection artifact of aerated lung below (Fig. 1). A standard 3.5 – 5 MHz probe is not able to distinguish the visceral and parietal pleura, unless they are separated (by a pleural effusion). However, this limitation does not mitigate the amount of clinically relevant information that pleural ultrasound provides. By scrolling longitudinally through intercostal spaces in each lung zone, the examiner can view most of the costal pleura. The pleural surface obscured by the rib shadows moves into the intercostal space with respiratory movement, rendering itself to examination [2].

LUNG SLIDING AND THE DIAGNOSIS OF PNEUMOTHORAX

The normal pleural line shimmers: a twinkling wave of movement moves across the pleural line with respiration. This is known as lung sliding and results from the movement of the two pleural surfaces against each other in reference to a fixed chest wall (video 3). The presence of lung sliding therefore implies that the two surfaces of the pleura are mobile and in apposition with no air present between them, at the location of the probe. It is important not to confuse movement of the chest wall for lung sliding. This is particularly crucial in the dyspneic patient with accessory muscle use. The M-mode can further help in detection of lung sliding. The characteristic pattern obtained is called the seashore sign (Fig. 2). Proportional to lung inflation, lung sliding increases from apex to base.

Pneumothorax is a frequently entertained diagnosis in the ICU and is often difficult to diagnose reliably in a prompt and safe manner. Detection of pneumothorax is further inhibited by the fact that most patients in the ICU are supine, thus limiting the diagnostic capability of a standard chest radiograph. A chest CT (with all the inherent problems of time lag, transportation and radiation exposure) has become the gold standard for this purpose. Ultrasound out-performs chest radiography and is comparable to CT in the evaluation of pneumothorax in the ICU patient [3].

Air rises to non-dependent areas in the pleural cavity. Ultrasound examination for pneumothorax should therefore begin in the corresponding area of the chest. By definition, lung sliding should be absent at the site of pneumothorax since the two pleural surfaces are no longer in direct contact as air is present between them [4, 5] (video 4). This can be confirmed by M-mode ultrasound through the pleural surface. Sea-shore sign will not be seen (Fig. 3). However, it is important to note that lung sliding may be absent due to a multitude of reasons other than pneumothorax; these include: pleural symphysis, the presence of apnea or complete atelectasis. On the other hand, the presence of lung sliding has a 100% negative predictive value for pneumothorax. That is, if lung sliding is present, it is not possible that pneumothorax is present in the location just beneath the probe [4]. If examination of the entire pleural surface, as delineated above, shows the presence of lung sliding, then pneumothorax can be confidently ruled out in that patient. An experienced sonographer can accomplish this within seconds, at the bedside without need for transporting the patient or waiting for a chest X-ray.

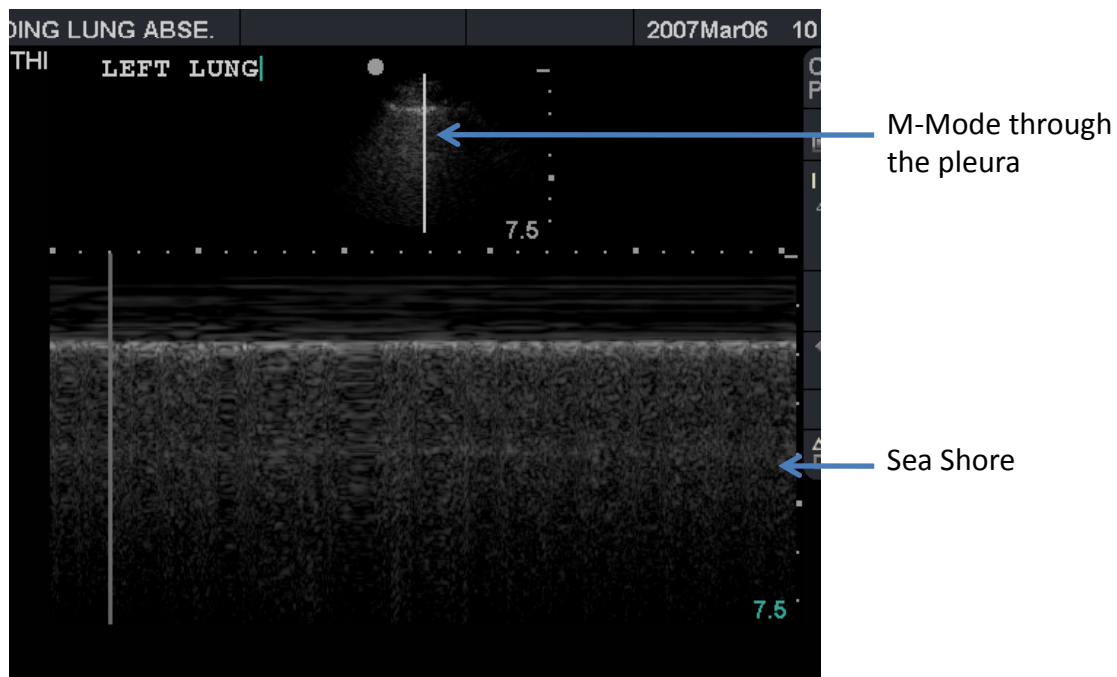


Fig. (2). M-mode placed through the pleural line generates the sea-shore sign. This is equivalent to the presence of sliding lung.

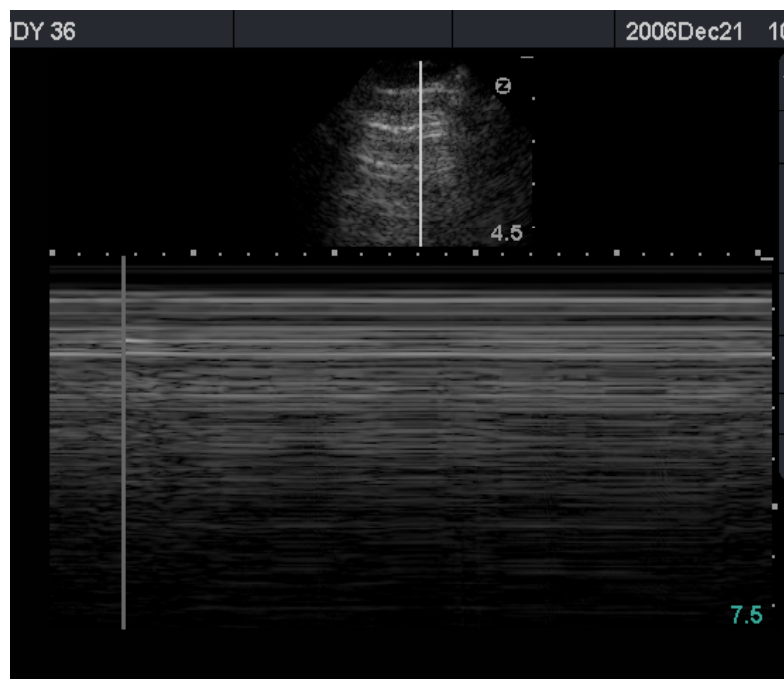


Fig. (3). A multitude of A-lines (parallel to the pleural surface and equidistant from each other) are seen. Absent lung sliding in combination with A-lines is a very specific sign for pneumothorax.

Other signs are helpful in the evaluation of pneumothorax. The presence of lung rockets (the reader is referred to the chapter on lung ultrasound in this supplement) is as sensitive as lung sliding in ruling out pneumothorax [1]. This is because lung rockets are artifacts generated by a thickened pulmonary interstitium and therefore imply the presence of underlying lung. In the absence of lung rockets, pneumothorax frequently results in an A-line pattern (see chapter on lung ultrasound). The combination of absent lung sliding and the A-line sign is 96% specific for the presence of pneumothorax [6] (Fig. 4).

Lung pulse is an interesting phenomenon that results from the transmission of cardiac pulsation to the pleura through the lung parenchyma [7]. The normal respiratory movement of the lung mitigates the visibility of lung pulse, so it is seen best during apnea. However, it also confirms the presence of lung under the pleura and therefore rules out pneumothorax with certainty.

Lung point has 100% specificity for pneumothorax [8]. Simply put, it is the point at the boundary of a pneumothorax where the visceral pleura starts to meet the parietal pleura.

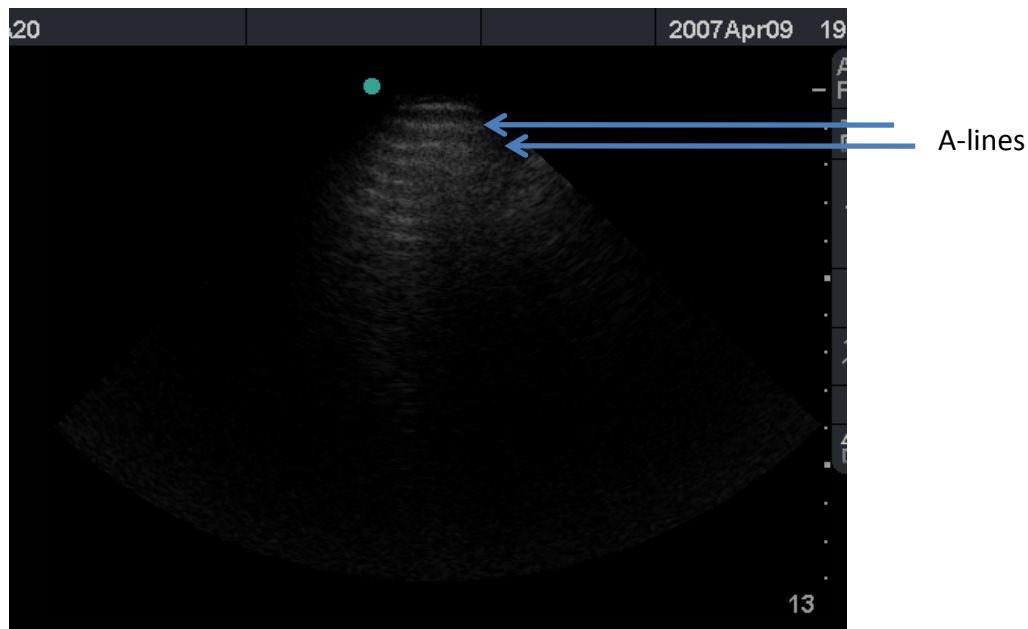


Fig. (4). A multitude of A-lines (parallel to the pleural surface and equidistant from each other) are seen. Absent lung sliding in combination with A-lines is a very specific sign for pneumothorax.

This means that at lung point, pulmonary signs such as lung rockets or lung sliding start to come in to view with each breath (videos 5, 6).

The ability to rule out pneumothorax without delay is critical for obvious reasons (see Table 1) and this capability can be used to rule out pneumothoraces after procedures that carry that inherent risk (such as central venous catheter placement or attempt, thoracentesis, bronchoscopy with transbronchial biopsy).

Table 1. Signs that Rule Out Pneumothorax (in the Area Being Evaluated)

1. Lung sliding
2. Lung rockets
3. Lung pulse

DIAGNOSIS OF PLEURAL EFFUSION

Ultrasonography has been used in the evaluation of pleural effusions for more than forty years. However, its application at the bedside in critical care has only recently gained some popularity. As opposed to air, free flowing fluid in the pleural cavity collects in the dependent portion of the thorax. Therefore, the search for a pleural effusion must begin near the diaphragm. A standard convention is followed: the probe is oriented longitudinally (cephalo-caudad) with the marker facing cephalad. The marker on the screen remains in the upper left corner.

Most pleural effusions are relatively anechoic collections. There are three cardinal rules for diagnosis of pleural effusions on ultrasound (see Table 2):

1. Identification of anatomic boundaries of pleural effusions: the chest wall, the diaphragm and sub-diaphragmatic organs, and the lung (Fig. 5).

Table 2. Cardinal Signs for Ultrasonographic Diagnosis of Pleural Effusions

1. Identification of anatomic boundaries	Chest wall anteriorly Diaphragm and sub-diaphragmatic organs (liver, spleen) inferiorly Lung
2. Relatively anechoic space	
3. Dynamic changes	Flapping lung (jellyfish sign) Sinusoid sign, Plankton sign, Hematocrit sign.

All three signs (any one of the dynamic changes is adequate) are necessary for diagnosis of a pleural effusion by ultrasound.

Table 3. Nature of Pleural Effusions on Ultrasound

Transudates	Anechoic
Exudates	1. Anechoic 2. Plankton sign 3. Strands 4. Septations 5. Homogenous echoes 6. Hematocrit sign

2. Relatively anechoic space (the effusion itself)
3. Dynamic changes (described below)

Flapping lung refers to the slow, undulating movement of compressed lung in the pleural effusion. It is sometimes also referred to as the jellyfish sign (video 7). This finding may be absent in very small effusions. In that case, aerated lung can be seen moving over the pleural effusion with respiration. The respiratory motion of the visceral pleura can also be visualized in M-mode. This oscillating movement towards and away from the chest wall with each breath

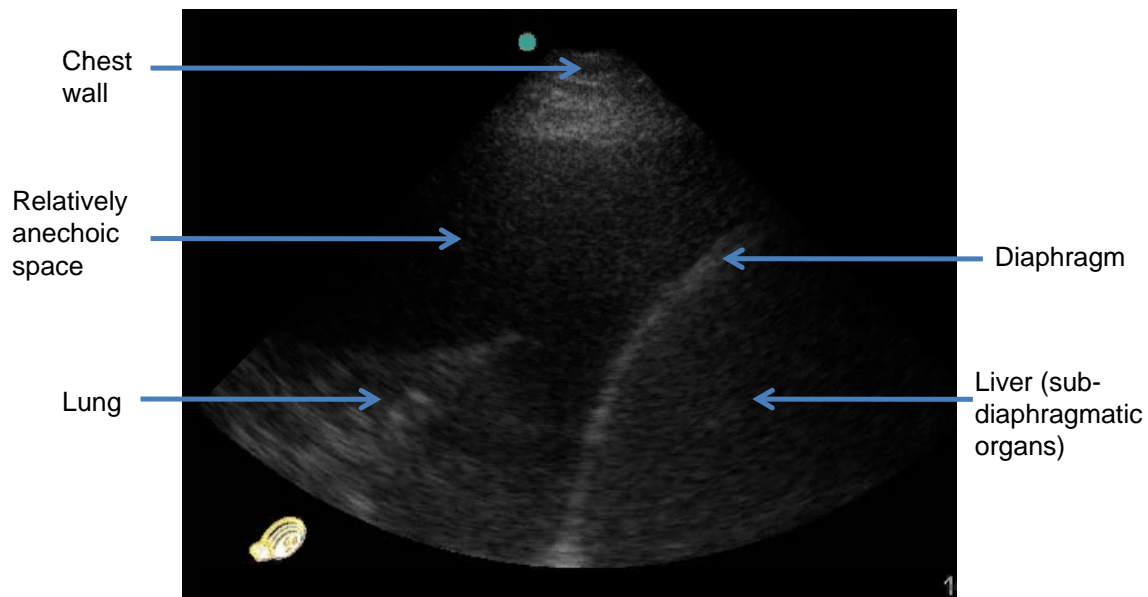


Fig. (5). The first rule for defining a pleural effusion is to identify the anatomic boundaries (the chest wall, the diaphragm and sub-diaphragmatic organs, and the lung).

creates a sinusoidal form in a time-motion tracing – the sinusoid sign (Fig. 6) which has a specificity of 97% for the diagnosis of pleural effusion [9].

The examiner should evaluate the entire thorax for the presence of a pleural effusion especially a loculated one. Ultrasound can identify even the smallest effusion (5mL) by this method [10]. Ultrasound clearly surpasses chest radiography in the diagnosis of pleural effusion [10, 11]. Moreover, most chest radiographs in the ICU are of relatively poor quality given the constraints in positioning the patient and presence of device artifacts.

TYPES OF PLEURAL EFFUSIONS

The nature of pleural effusions on an ultrasound image has clinical relevance (see Table 3). All transudative effusions are echo free. Exudates can be anechoic but frequently have some level of echogenicity. This may take many forms. Echogenic debris can float in an otherwise anechoic effusion - plankton sign (video 8). Fibrinous strands may be seen flapping in the pleural effusion (video 9) and sometimes septations are visible [12] (Fig. 7 and video 10). These are often suggestive of a purulent effusion [13].

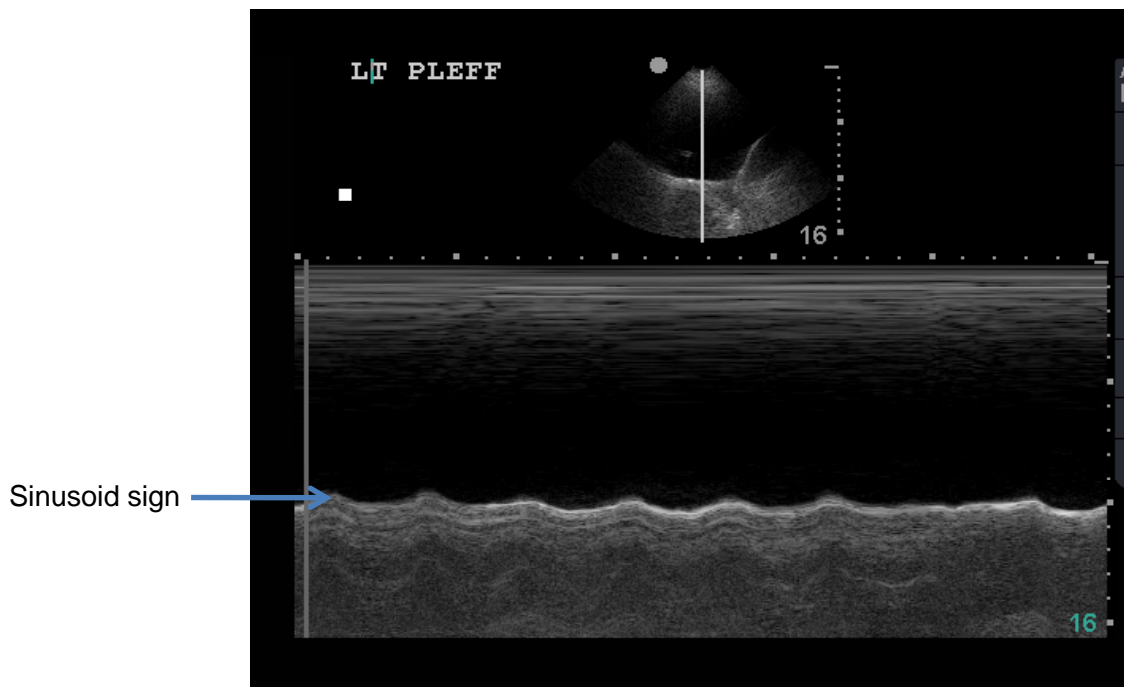


Fig. (6). Undulating movements of the lung and visceral pleura in a pleural effusion generate the sinusoid sign in M-mode ultrasound.

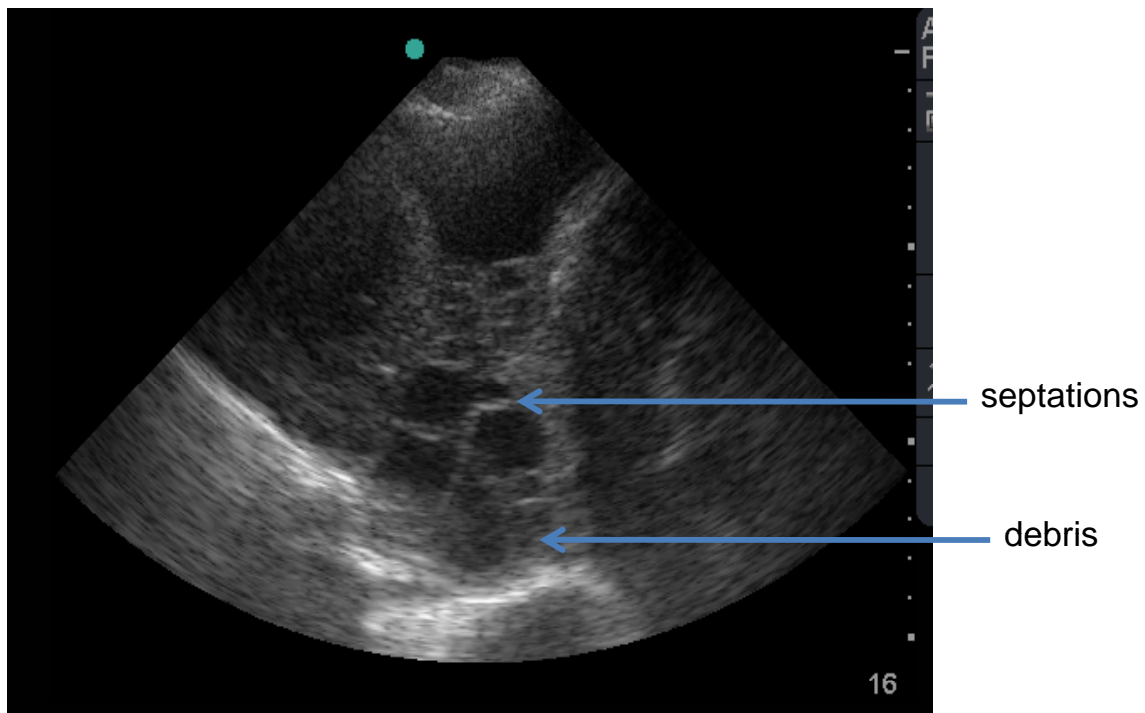


Fig. (7). Complex pleural space with septations and debris.

Very cellular or purulent effusions can generate uniform echoes giving a tissue-like appearance. It is possible to distinguish this from solid organs by the identification of dynamic signs discussed above. Sometimes cellular debris settles out in the dependent portion of an effusion - the hematocrit sign - which is highly suggestive for the presence of a hemothorax or another cellular effusion such as a malignant one (video 11).

SOLID PLEURAL ABNORMALITIES

Pleural tumors may be benign or malignant, single or multiple, occasionally with an accompanying pleural effusion (video 12). These are easily visible on ultrasound but ultrasonographic appearance cannot definitively diagnose the pathology. It can however, evaluate diaphragmatic or chest wall involvement. Ultrasound can also guide transthoracic biopsy of pleural tumors if an appropriate window for safe access with a needle can be identified.

PROCEDURAL APPLICATIONS – THORACENTESIS

Ultrasound guidance of thoracentesis is routine. It is now evident that non-radiographers can do this safely [2]. The first step is to identify a pleural effusion unequivocally (see above). The inexperienced sonographer may be fooled by peritoneal fluid or worse still mistake the liver or spleen for an echogenic effusion. The operator can avoid this disastrous mistake by always following the cardinal rules for identifying a pleural effusion. The landmarks should all be seen, the liver or spleen should be located, and the heart, aorta, and kidney should always be identified and avoided. Due to respiratory motion, the lung may move in and out of the field. The operator must be cautious and observe carefully for a sufficient time to identify this. Next, an appropriate site for puncture has to be identified. There is no minimum requirement for depth of effusion for thoracentesis

with some authors recommending a minimum depth of 15mm [1].

The procedure is usually easiest to perform with the patient in either a sitting or lateral decubitus position. However, this is not always feasible in the ICU. Therefore, any position which provides an appropriate window for thoracentesis and can be safely maintained by the patient is acceptable. Thoracentesis is performed with the patient in the same position as during ultrasound localization, thus avoiding movement of effusion and loss of appropriate window. The site is clearly marked making note of skin compression and movement artifact. The angle of the needle at the point of entry must be the same as that of the ultrasound probe at the time of site localization. Both diagnostic and therapeutic thoracentesis are safely performed in this manner (see Table 4).

Table 4. Summarization of Steps in Ultrasound Guided Thoracentesis

1. Identify pleural effusion – cardinal rules
2. Patient position – safe, comfortable, stable
3. Operator position – safe, comfortable, stable
4. Identification of site and depth of fluid
5. Identification of vital organs to be avoided
6. Site localization and memorization of angle of probe
7. Needle insertion at an angle identical to angle of the probe

Ultrasound guidance increases the safety of thoracentesis and minimizes failure rate. Ultrasound has been shown to be superior to physical examination and chest radiography for site localization [14]. It is safe to perform this procedure in mechanically ventilated patients [9, 15].

OTHER PROCEDURAL APPLICATIONS

Ultrasound guidance is used to perform many other procedures. These are best carried out by experienced operators. Some examples include:

1. Placement of temporary as well as indwelling catheters for drainage of pleural fluid
2. Pleural biopsy
3. Mechanical septal lysis in a complex pleural effusion

SUPPLEMENTARY MATERIAL

This article contain 12 video files and it can be viewed at www.bentham.org/open/toccmj

REFERENCES

- [1] Lichtenstein DA. General ultrasound in the critically ill. New York: Springer-Verlag 2002.
- [2] Mayo PH, Doelken P. Pleural ultrasonography. *Clin Chest Med* 2006; 27: 215-27.
- [3] Lichtenstein DA, Meziere G, Lascols N, *et al.* Ultrasound diagnosis of occult pneumothorax. *Crit Care Med* 2005; 33: 1231-8.
- [4] Lichtenstein DA, Menu Y. A bedside ultrasound sign ruling out pneumothorax in the critically ill. *Lung Sliding* 1995; 108: 1345-8.
- [5] Rantanen NW. Diseases of the thorax. *Vet Clin North Am Equine Pract* 1986; 2: 49-66.
- [6] Lichtenstein D, Meziere G, Biderman P, Gepner A. The comet-tail artifact: an ultrasound sign ruling out pneumothorax. *Intensive Care Med* 1999; 25: 383-8.
- [7] Lichtenstein DA, Lascols N, Prin S, Meziere G. The lung pulse: an early ultrasound sign of complete atelectasis. *Intensive Care Med* 2003; 29: 2187-92.
- [8] Lichtenstein D, Meziere G, Biderman P, Gepner A. The lung point: an ultrasound sign specific to pneumothorax. *Intensive Care Med* 2000; 26: 1434-40.
- [9] Lichtenstein D, Hulot JS, Rabiller A, Tostivint I, Meziere G. Feasibility and safety of ultrasound-aided thoracentesis in mechanically ventilated patients. *Intensive Care Med* 1999; 25: 955-8.
- [10] Grymiski J, Krakowka P, Lypacewicz G. The diagnosis of pleural effusion by ultrasonic and radiologic techniques. *Chest* 1976; 70: 33-7.
- [11] Kelbel C, Borner N, Schadmand S, *et al.* Diagnosis of pleural effusions and atelectases: sonography and radiology compared. *Rofo* 1991; 154: 159-63.
- [12] McLoud TC, Flower CD. Imaging the pleura: sonography, CT, and MR imaging. *Am J Roentgenol* 1991; 156: 1145-53.
- [13] Tu CY, Hsu WH, Hsia TC, *et al.* Pleural effusions in febrile medical ICU patients: chest ultrasound study. *Chest* 2004; 126: 1274-80.
- [14] Diacon AH, Brutsche MH, Soler M. Accuracy of pleural puncture sites: a prospective comparison of clinical examination with ultrasound. *Chest* 2003; 123: 436-41.
- [15] Mayo PH, Goltz HR, Tafreshi M, Doelken P. Safety of ultrasound-guided thoracentesis in patients receiving mechanical ventilation. *Chest* 2004; 125: 1059-62.

Received: April 15, 2009

Revised: May 15, 2009

Accepted: June 2, 2009

© Chandra and Narasimhan; Licensee *Bentham Open*.

This is an open access article licensed under the terms of the Creative Commons Attribution Non-Commercial License (<http://creativecommons.org/licenses/by-nc/3.0/>) which permits unrestricted, non-commercial use, distribution and reproduction in any medium, provided the work is properly cited.