

Clinical Applications of ICG Fluorescence Imaging in Plastic and Reconstructive Surgery

Charlotte Holm*

Department of Plastic and Aesthetic Surgery, ATOS Private Clinic Munich, Effnerstrasse 38, D-81925 Munich, Germany

Abstract: *Aims and Background:* Compromise in blood supply and failure in tissue transfer are associated with excessive resource costs in plastic surgery. The ability to detect impaired blood supply on the table would contribute to major cost savings for the health care system. Indocyanine green imaging (ICGA) holds promise as a simple method with a high sensitivity and specificity for assessing blood flow in the operating room.

Methods: In this review, experimental and clinical studies concerning the use of ICGA in the field of plastic and reconstructive surgery are reviewed.

Findings: Possible plastic surgical applications of ICGA range from assessment of flap perfusion in pedicle and free flap surgery to patency assessment of microvascular anastomoses, sentinel node detection, lymph vessel identification, and burn depth estimation.

Conclusions: At present ICGA offers the best data-supported estimates of blood supply in reconstructive plastic surgery. Substantial evidence exists that intraoperative ICGA improves the quality of plastic surgical procedures and has the potential to reduce peri- and postoperative morbidity significantly.

Keywords: Plastic and reconstructive surgery, ICG fluorescence imaging, intraoperative imaging technique, microvascular anastomosis, flap perfusion in graft.

Considerations about blood supply dominate almost all aspects of reconstructive surgery. Within the limits imposed by the demands of the circulation and consequent tissue viability, the plastic surgeon constantly tries to achieve the most advantageous cosmetic and functional result. Skill in reconstructive surgery is very much a matter of ensuring flap blood supply on the table in order to avoid post operative complications and vascular compromise [1]. No matter if pedicle of free tissue transfers; - an early detection of vascular compromise with prompt correction remains critical in the success of any plastic surgical procedure. Still, the art of plastic surgery is an empiric one, where design and assessment of blood supply are based on subjective evaluation rather than objective scientific data. Rigid rules on the most appropriate flap design exist, but are subject to substantial personal interpretation, leaving the actual surgical approach to flap surgery with great interindividual difference. Also in reconstructive microsurgery, where the success of surgery relies on the patency of the anastomoses, no objective measures are available for the assessment of vascular flow. Here, evaluation relies on clinically based subjective criteria's and on clinical patency tests, even though these measures have been shown to have a low sensitivity for revealing luminal obstruction [2].

Healthcare faces hitherto unseen challenges from increasing costs and the drive to increase efficiency. Given that failure in tissue transfer has been shown to be associated with longer hospital stays and excessive resource costs, there is no doubt that the routine implementation of an objective, validated technique to assure flap perfusion in the operating room would contribute to major cost savings for the health care system. This would represent a significant improvement in quality assurance. As shown by studies in other specialties, including cardiac and neurosurgery, intraoperative imaging techniques using ICG fluorescence have the potential to improve the quality of surgery and reduce peri- and postoperative morbidity significantly [3-5].

The ideal flap evaluation system for plastic surgical purposes would have a high specificity and sensitivity for detecting compromised perfusion, have a high prognostic informative value for predicting tissue necrosis, and would be able to accurately distinguish between arterial and venous compromise in a timely fashion. Compared with other monitoring techniques like Doppler, tissue oximetry, or ultrasound, ICGA comes close to meeting these criteria's. Possible applications range from assessment of flap perfusion in pedicle and free flap surgery to patency assessment of microvascular anastomoses, sentinel node detection, lymph vessel identification, and burn depth estimation.

Based on several years of experience with different imaging techniques using ICG fluorescence the intent of this review was to provide an overview over possible applications of ICGA in the field of plastic and reconstructive surgery.

*Address correspondence to this author at the Department of Plastic and Aesthetic Surgery, ATOS Private Clinic Munich, Effnerstrasse 38, D-81925 Munich Germany. Tel: +49 89 20 4000 200, Fax: +49 89 20 4000 299; E-mail: charlotte_holmjakobsen@hotmail.com

INDOCYANINE GREEN

Indocyanine green is water soluble, tricarboyanine dye. After intravenous injection it is efficiently removed from the blood by the liver and excreted into the bile. It has been used for more than 40 years for measuring cardiac output, as a liver function test, and for fluorescence angiography of the choroidea. In the intensive care medicine it has been used for hemodynamic monitoring and measuring of intravascular volumes. Plastic surgical applications in the field of intensive care medicine include the guidance of shock resuscitation in patients with burns [6,7].

Indocyanine dye absorbs light in the near-infrared spectral range with a maximum at 805 nm and emits fluorescence with a maximum at 835 nm. These absorption and emission qualities lie in the "optical window" of the skin, where the absorption of intrinsic chromophores like haemoglobin and water is low. Thus, Indocyanine green fluorescence occupies a "biological spectral window" that allows excellent visualization of deep structures in the living body. Penetrating deeper into the skin, the excitation light induces fluorescence from blood vessels within the deep dermal plexus and subcutaneous fat instead of only the superficial dermis (as with fluorescein). Detection of blood vessels at a depth up to 2 cm from the body surface has been previously shown. Because the skin is relatively transparent to the ICG fluorescence wavelength, the induced fluorescence is not trapped in the skin and can be recorded by a suitable camera.

The favorable pharmacokinetic properties of indocyanine green present a further advantage of this tracer. After intravenous injection it binds almost completely to large plasma proteins, allowing complete intravascular localization of the dye [8]. This makes it a suitable tracer for vessel perfusion in healthy patients without capillary leakage. The very short half-life of 3-4 minutes allows for sequential monitoring of skin perfusion with short intervals between injections. Previous examinations therefore do not prevent repeated measurements.

The incidence of adverse reactions after intravenous or intraarterial injection is very low (1: 42.000) [9]. ICG has no effects on blood constituents or on the hemostatic system and does not display toxicity at doses < 5 mg/kg. Usual doses used for perfusion imaging purposes lie in the range of 0.1 to 1 mg/kg.

ICG was first used to evaluate perfusion by Flower and Hochheimer in 1976 [10]. Since then, a large number of experimental and clinical studies have been published on ICGA. Due to the great emphasis of blood supply in plastic and reconstructive surgery, a significant number of the experimental and clinical studies are centered on plastic surgical procedures.

IMAGING TECHNIQUES

Different near infrared video camera systems have been described for ICGA. These include the ICView System (*Pulsion Medical Systems, Munich*), the PDE System (*Hamamatsu Photonics K.K. Hamamatsu Japan*), and the SPY System (*Novadaq Technologies, INC*). Common to these imaging systems is the activation of ICG by the

emission of light at the according wavelength and the filtering of light to detect the fluorescence signals efficiently.

Recently, the German medical company Zeiss succeeded to integrate the indocyanine green technology into the optical path of a surgical microscope (*OPMI Pentero IR800, (Carl Zeiss Co., Oberkochen Germany)*). This new technology opened new doors in indocyanine green imaging. Color microangiographies of vessels with a diameter less than 1 mm were suddenly available and visualization of vascular flow through the anastomotic site became possible for the first time. Practically, a special arrangement of filters allows the passage of near infrared light from a modified microscope light source into the surgical field and the passage of ICG fluorescence from the surgical field back into the optical path of the surgical microscope.

Pedicle Flap Surgery

Adequate blood circulation is a significant determinant of morbidity and healing characteristics in pedicle flap surgery. While flaps with an adequate blood supply heal in uneventful, flaps with local or global hypoperfusion run a significant risk of postoperative skin slough, wound dehiscence, and other ischemia related complications [1]. Still, evaluation of flap perfusion is based on subjective rather than objective criteria and rely on visual and tactile characteristics like tissue color, capillary refill, and dermal bleeding.

Clinical evaluation, however, can be inaccurate, even for experienced practitioners. A timely recognition of inadequate circulation on the table has significant implications, as surgical delay of the flap may be able to prevent postoperative complications [11]. A surgical delay consists in a putting back the flap to the original position, thereby avoiding the strain of the transfer, while dividing all other vessels than those, on which the flap is going to rely. Transfer of the flap into the defect is postponed for several days.

Several measures have been described for the intraoperative assessment of flap perfusion. These include measurement of skin temperature, blood velocity, transcutaneous oxygen monitoring, and ultrasonic Doppler. However, most of these methods have not found widespread acceptance, probably due to a lack of convincing evidence of efficacy [12]. At present ICG video angiography offers the best data-supported estimates of blood supply in random pattern and axial flap surgery [13-16]. ICGA is unique in that it offers a dynamic map of dermal circulation, providing a detailed topographical analysis of the effective blood supply to the flap tissue (Fig. 1). Differences in perfusion between normal and flap skin yields a "perfusion index", which in several studies has been shown to be indicative of postoperative complications [13-16]. Differentiation between arterial and venous vascular compromise is possible based on fluorescence intensities and clearance characteristics when compared to the surrounding skin. Recent sophisticated experimental studies describe an exact quantification of arterial inflow and venous outflow based on contrast-to-background ratio curves [17].

For the clinician, however, a quantification of fluorescence intensities on the table is only then important,

when the clinical relevance of different perfusion values has been proven. Unfortunately, the establishment of critical perfusion threshold values has proven to be a difficult task, as dye filling defects are not always associated with a compromised healing or tissue sloughing. Even though in experimental studies, a perfusion index threshold value of 25% has been demonstrated [18,19]. clinical findings are less consistent [14,15,20]. This is probably due to the fact that the ICGA measurement represents a snap-shot of the tissue perfusion to a given point of time. Perfusion values may fluctuate for any given patient as a result of variations in systemic hemodynamics, cardiac output, body temperature, and the administration of intravenous drugs. This has raised the question whether ICGA is *too* sensitive for the realistic prognosis of complications, upon which the decision to intervene intraoperatively might rest [20].

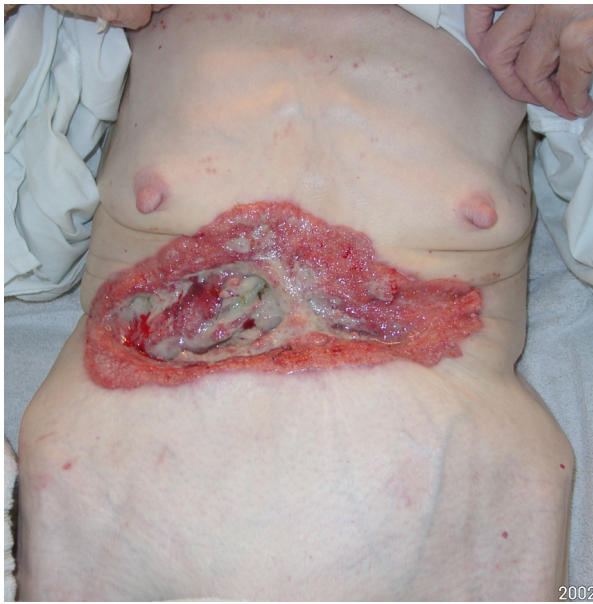

Fig. (1a). 6-year old female with an exulcerating squamous cell carcinoma of the abdominal wall.

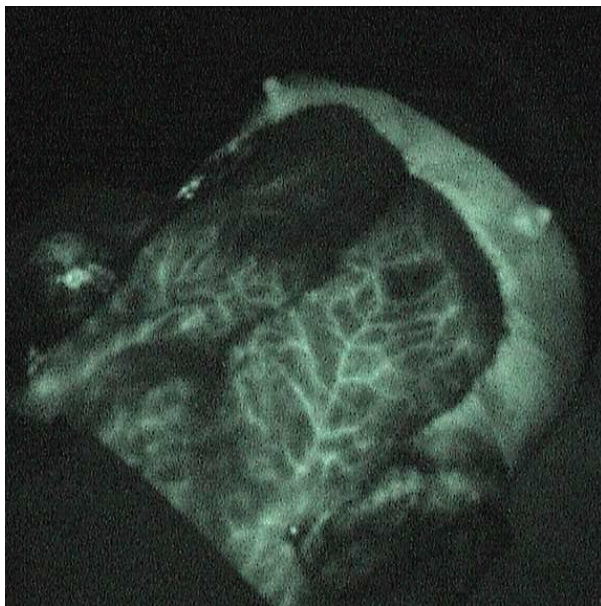


Fig. (1b). Palliative resection of the tumor and coverage with bilateral pedicle groin flaps.

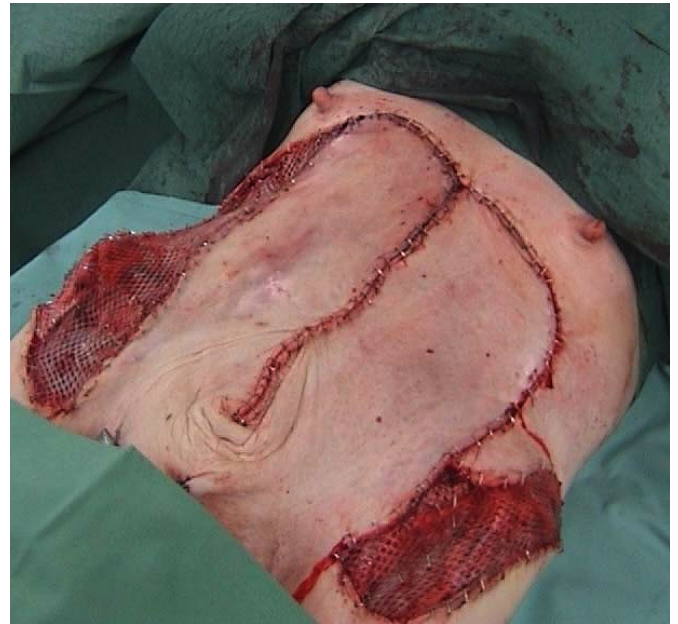

Fig. (1c). Intraoperative ICG angiography (ICGA) demonstrating the strong axial arterial system.

Nevertheless, even when exact critical perfusion values have not yet been established, there is no doubt that dye filling defects on the table are a serious warning signal of significantly compromised tissue perfusion. Based on our large clinical experience, a compromised ICGA measurement should always be taken seriously and should at least be associated with a reconsideration of the surgical plan (Figs. 2, 3). A surgical delay of a pedicle flap is an easy approach, which might be able to prevent the occurrence of postoperative complications.

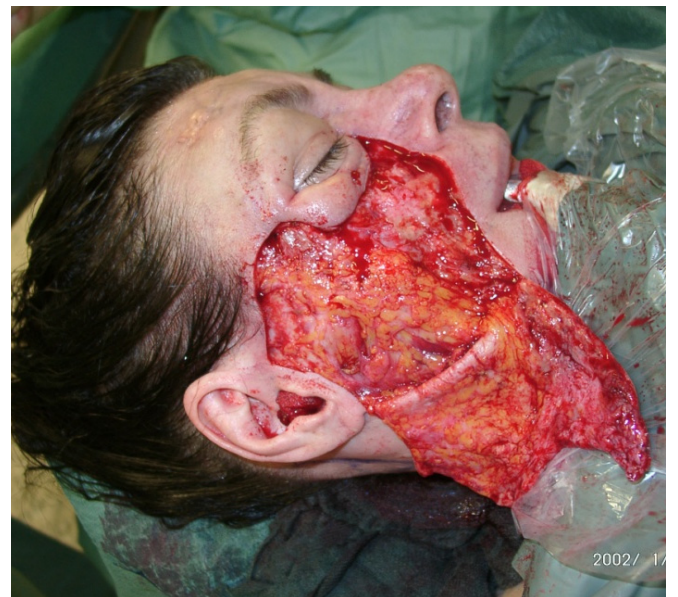

Fig. (2a). Clinical photograph of a combined rotation-transposition flap in a 51 year old female with after radical resection of multiple siliconomas of the facial skin.

Aesthetic Surgery

A smooth postoperative course and a postoperative lack of complications is a goal of crucial importance in aesthetic

surgery. Knowing that blood circulation on the table is a significant determinant of postoperative morbidity, intraoperative ICGA is very useful for quality assurance in cosmetic surgical procedures.

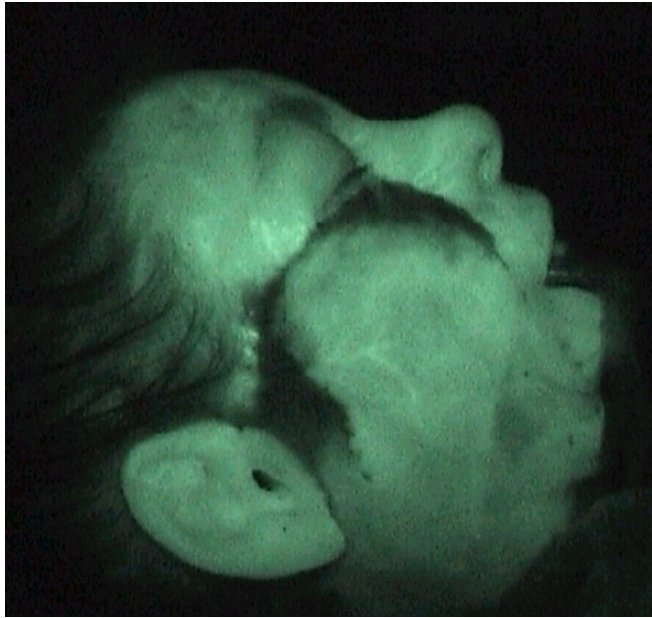

Fig. (2b). The flap after inset and suturing.

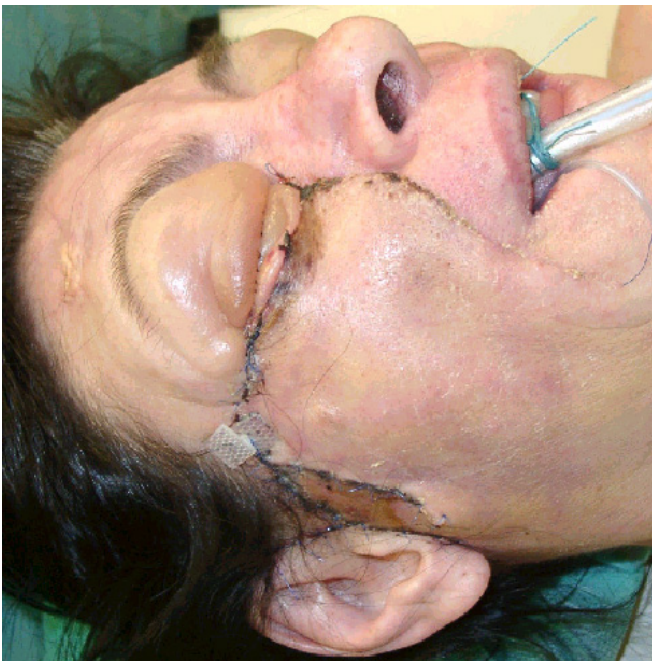

Fig. (2c). Intraoperative ICGA demonstrating obvious filling defects of the preauricular transposition flap and of the distal part of the cheek flap.

Abdominoplasty is a classical example of an aesthetic procedure, where ischemia-related complications are relatively frequent. In a clinical study with patients undergoing aesthetic abdominoplasty, we used indocyanine angiography to study the impact of excessive undermining on the perfusion of the abdominal skin [21]. The result of quantitative perfusion measurements showed a dramatically reduced blood supply to the skin in the suprapubic area

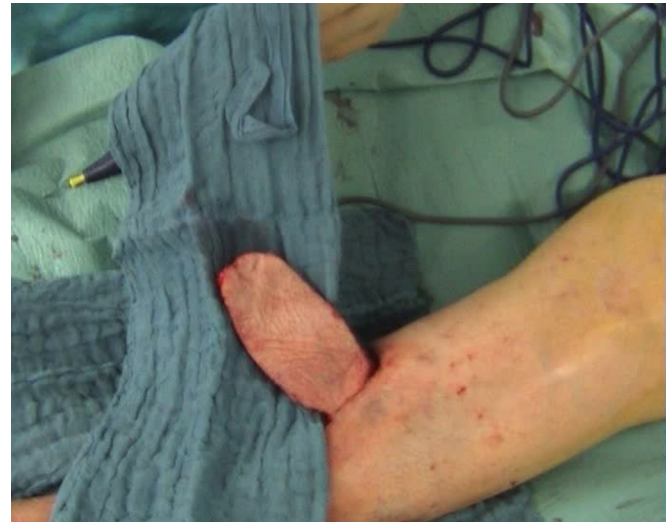

Fig. (3a). Clinical photograph of a propeller flap for coverage of a defect of the lower leg. Clinically, the perfusion looked adequate.



Fig. (3b). Intraoperative ICGA showing filling defect of the distal half of the flap.

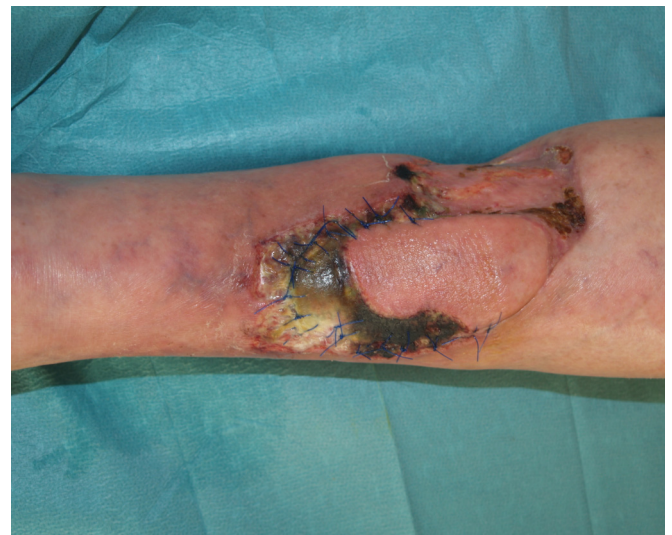

Fig. (3c). Clinical outcome after 1 week obvious necrosis of the area with intraoperative dye deficit.

(Fig. 4). Based on the results of this study, a technical modification of the conventional operative technique was proposed, changing the operative approach from an extended undermining up to the costal margin to a limited triangular dissection from the xiphoid to the anterior superior iliac spine. The intraoperative angiograms demonstrated a significant improvement of overall skin perfusion when limiting the dissection, probably due to the presevation of some musculocutanous and intercostal perforating vessels. This was able to reduce the incidence of postoperative ischemia-related complications significantly.

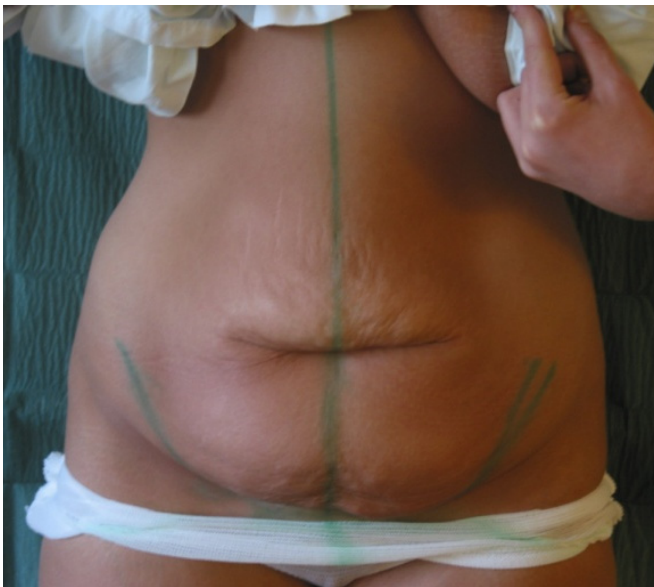

Fig. (4a). A 26-year-old woman with musculofascial and skin laxity following a 50-kg weight loss.

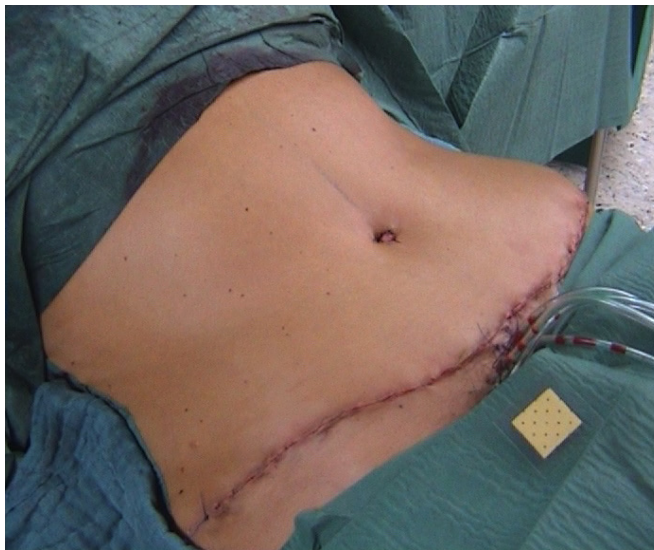

Fig. (4b). Intraoperative view shortly after finishing the abdominoplasty with undermining of the abdominal skin from the suture line up to the costal margin.

Although not yet clinically demonstrated, ICGA has the potential to provide technical modifications to other aesthetic procedures as well, especially when the operative technique is associated with extensive skin undermining like in facelift or other skin tightening procedures.

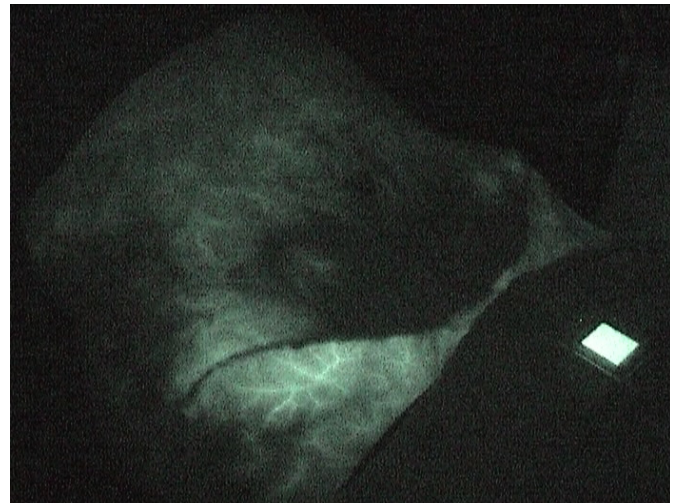


Fig. (4c). Intraoperative ICGA demonstrating a dramatically reduced blood supply to the skin in the suprapubic area.

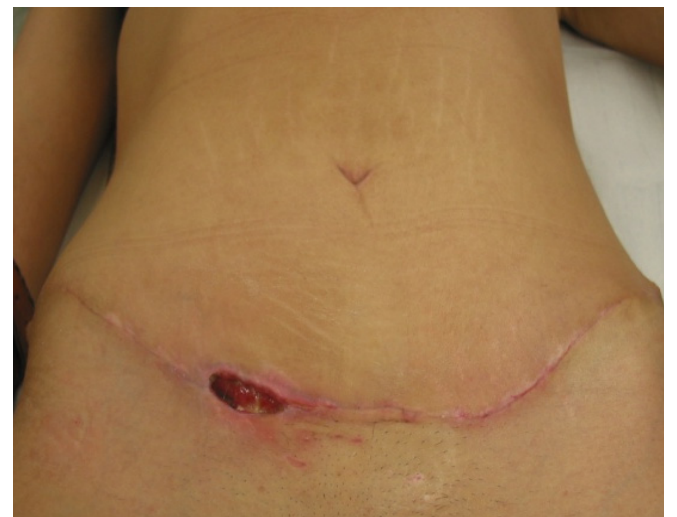

Fig. (4d). Three weeks after abdominoplasty the patient shows wound dehiscence and skin necrosis in the infraumbilical area.

Reconstructive Microsurgery

The blood supply of free flaps is thoroughly dependent on the flow in the pedicle vessels. When considering the free flap the target organ supplied by these vessels, ICGA can be used for visualisation of the effective blood supply to this target. Obstruction of inflow leads to a total lack of dye staining of the flap (Figs. 5, 6); outflow obstruction is demonstrated by a delayed clearance of dye when compared with the surrounding skin. Further differentiation of compromises of in-and outflow is possible based on the intraoperative angiogram, including arterial vasospasm, venous congestion and kinking of the pedicle vessels [22-25].

ICGA in microsurgical cases, however, is not always based on an all-or-nothing description of perfusion. Given that the anastomoses are patent and the pedicle vessels intact, ICGA provides significant additional information about the distribution of blood flow to the flap and the territory of skin supplied by the axial pedicle vessel. Such knowledge about the survival area provided by a given axial artery is essential to the surgeon, especially when raising extended flaps like the lower abdominal, where the blood supply provided by

the axial vessel is mostly inadequate to nourish all zones of the flap. In the field of microsurgical autologous breast reconstruction, ICGA has shown to be extremely important for decision-making in tailoring and inseting of the flap when creating the breast mound (Fig. 7). We have used ICGA in a series of clinical studies on the angiosome of the superficial and deep inferior epigastric artery, and the results have had significant impact on operative strategies in reconstructive breast surgery [26-28].

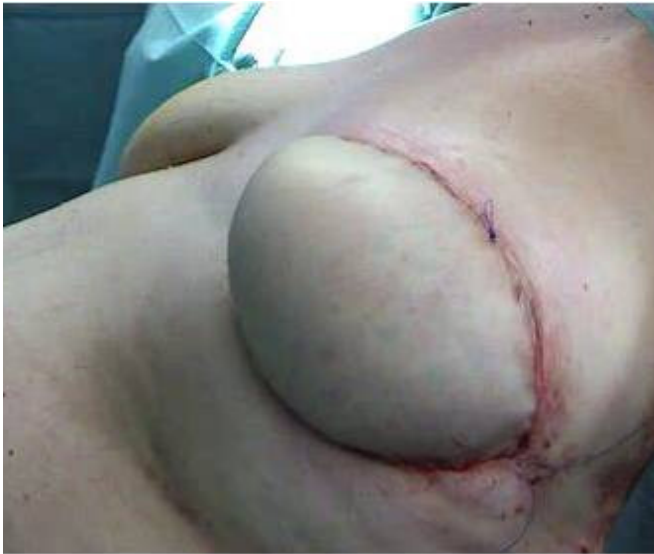

Fig. (5a). Free deep inferior epigastric perforator flap (DIEP) after inseting and suturing of the anastomoses.

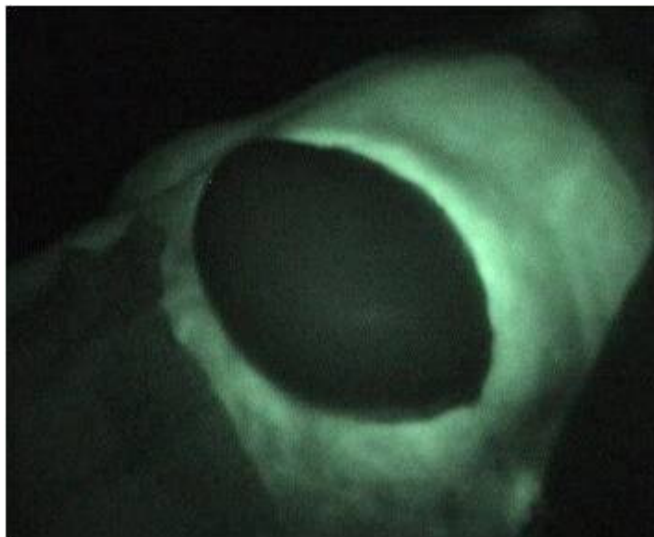

Fig. (5b). Intraoperative ICGA demonstrating total occlusion of the arterial anastomosis with a total lack of dye filling of the flap. Anastomotic revision revealed severe kinking of the arterial pedicle.

Indocyanine green microangiography (ICGMA) represents a further refinement of the ICGA technique. This measure is based on the technical integration of the near-infrared video system into the optical path of a surgical microscope, and enables a direct visualisation of vascular flow through the anastomoses instead of the indirect assessment of dye distribution within the target organ (Fig. 8). As conventional angiography of vessels with submillimeter

diameter was hitherto unavailable in microsurgical cases, ICGMA represents the first approach to quality assurance in the field of reconstructive microsurgery. Considering the fact that anastomotic patency is the predominant determinant of free flap survival, it is obvious that the possibility to objectively assess the quality of the microvascular anastomoses has the potential to improve the quality of microsurgical procedures and reduce the incidence of reexploration surgery and free flap failure significantly.

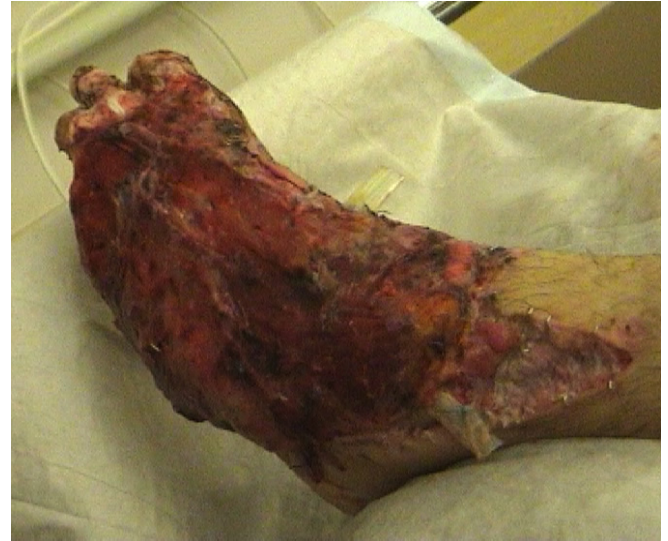

Fig. (6a). Free latissimus dorsi muscle flap demonstrating poor perfusion 7 days postoperatively.

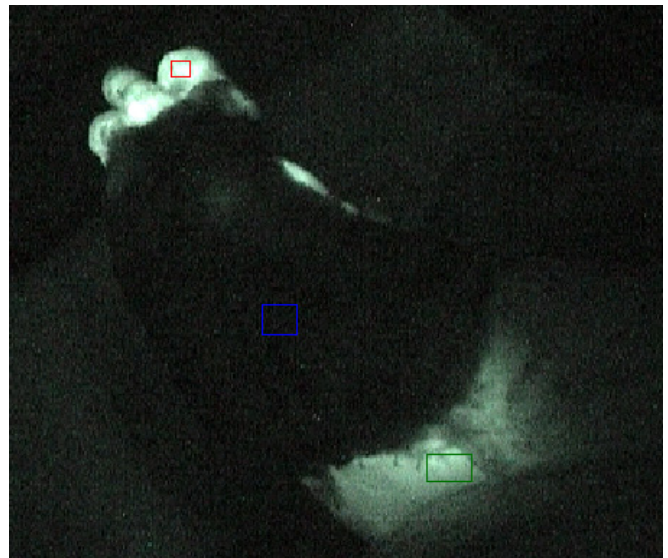


Fig. (6b). ICGA demonstrating a total lack of perfusion. Surgical exploration revealed total thrombosis of the arterial and venous pedicle.

Inspired by the first clinical studies in neuro-and cardiac bypass surgery, where the flow through cerebral and coronary vessels could be visualised with excellent temporal spatial and temporal resolution [3,4], we performed the first clinical studies on ICGMA in 2008 [29,30]. In a large series of patients undergoing reconstructive microsurgery we were able to prove an unexpected high incidence of different technical failures associated with the suturing of

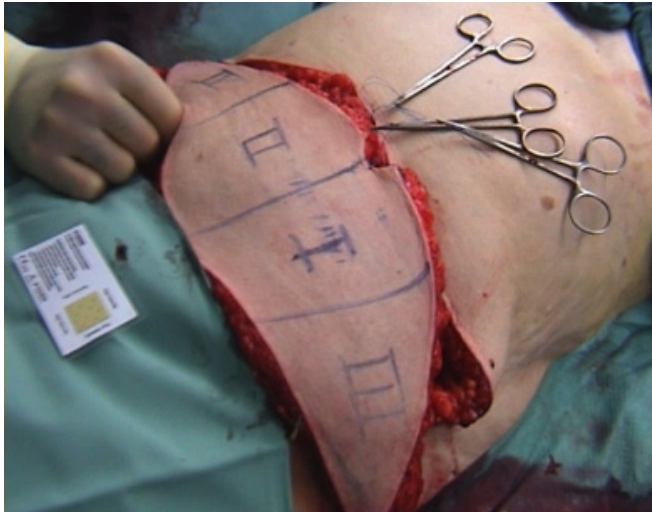


Fig. (7a). Free deep inferior epigastric artery perforator flap after isolation on two perforator arteries from the left inferior epigastric artery. The conventional Hartrampf perfusion zones are marked on the skin with ink.

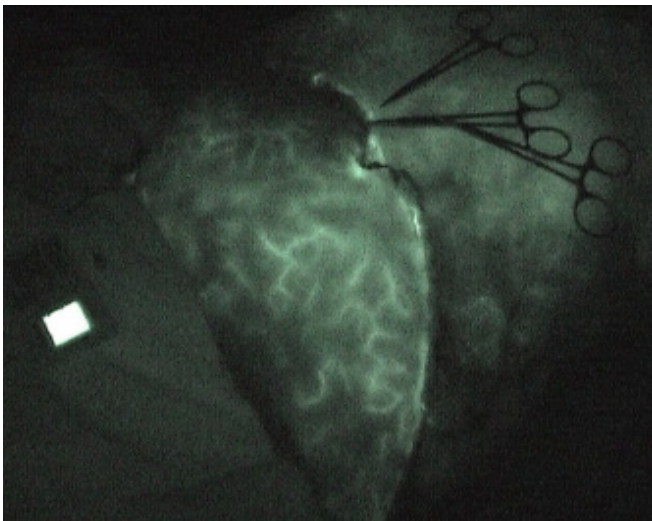


Fig. (7b). ICG-angiography 42 seconds after injection showing dye filling of zone I-III. Perfusion defects of zone IV are seen.

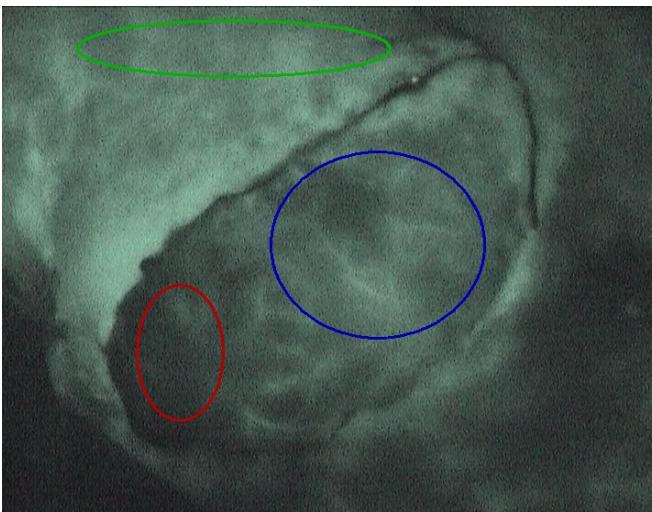


Fig. (7c). Persistent perfusion deficit of zone IV after finishing the microvascular anastomoses and inset of the flap.

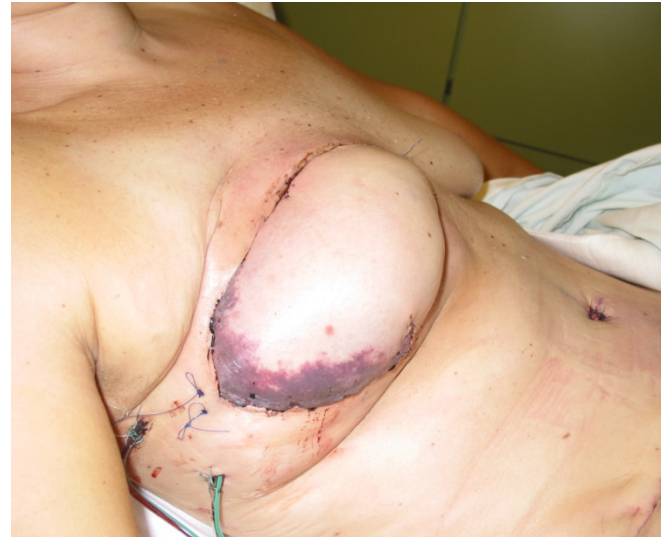

Fig. (7d). Partial flap necrosis (zone IV) 1 week after flap transfer.

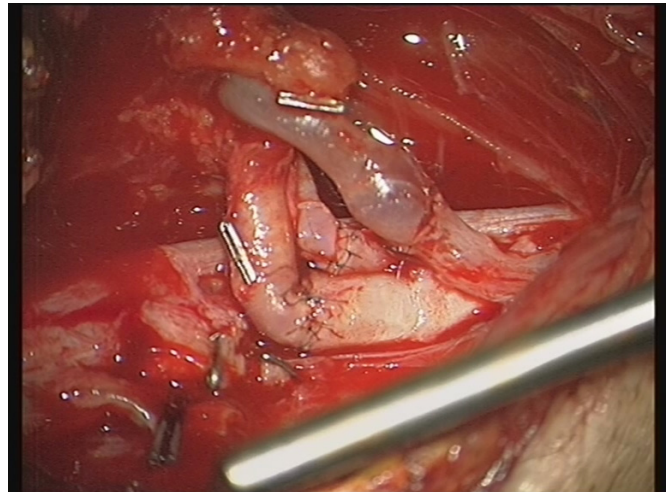


Fig. (8a). Microvascular anastomoses including one end-to-end arterial and two venous anastomoses.



Fig. (8b). Indocyanine green microangiography (ICGMA) (arterial phase) demonstrating full patency of the arterial anastomosis.

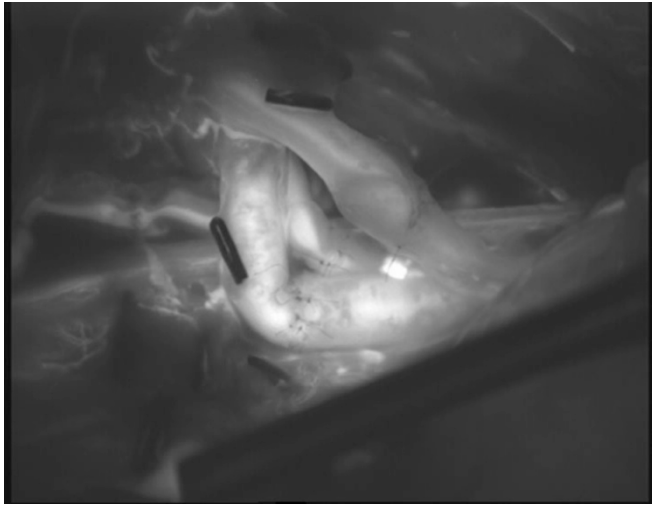


Fig. (8c). Microangiography (venous phase) demonstrating full patency of both of the venous anastomoses.

microsurgical anastomoses, and the urgent need for intraoperative quality assurance previously demonstrated in neuro- and cardiac surgical patients was confirmed (Fig. 9). Conventional subjective patency tests consisting in double forceps test and clinical inspection were shown to have a very low sensitivity for revealing anastomotic imperfection, as 22% of anastomoses classified as patent showed an abnormal flow through the anastomotic site.

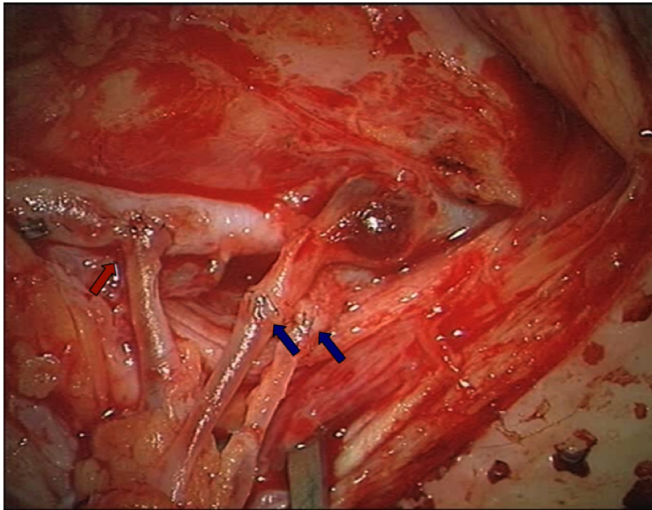


Fig. (9a). Microvascular anastomoses including one end-to-side arterial (red arrow) and two venous (blue arrows) anastomoses.

Based on these data and on studies on early re-exploration rates of 6-14% in reconstructive microsurgery, it seems probable that with routine implementation of intraoperative ICG imaging it would be possible to identify most of these failures already on the table. The potential impact on postoperative outcome and early re-exploration rates is significant, and should be evaluated in future studies.

PREOPERATIVE PERFORATOR MAPPING

Perforator flaps represent an important conceptual change in reconstructive surgery. A perforator flap is based on one or two perforating vessels, rather than being based on all of the perforators and all the underlying (muscle)tissue.

The advantages include a minimal donor site morbidity and flexibility of the procedure, resulting in a faster recovery for the patient. The disadvantages include an increased risk to flap viability due to a high degree of variability in perforator vessel anatomy. This has made a precise preoperative detecting of vessel anatomy more important than before. During the last few years, several studies have been published which prove the efficacy of preoperative mapping of perforators in reducing operative times and complications in microsurgical perforator flap reconstruction [31]. Most of these studies use three dimensional computed tomographic angiography, which has established as gold standard for preoperative imaging of vessel anatomy.

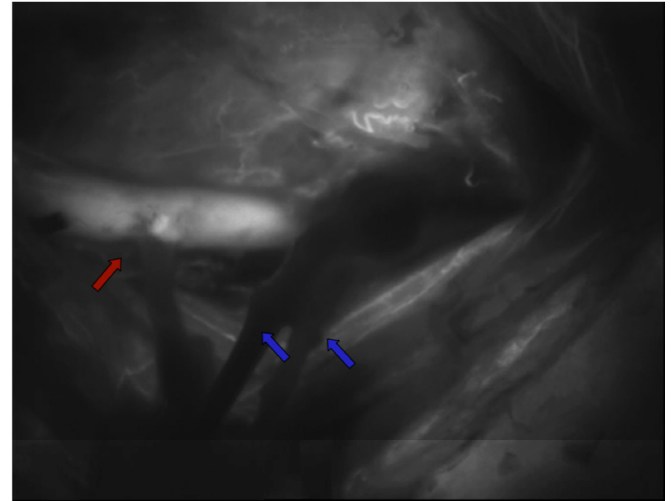


Fig. (9b). Representative microangiography demonstrating total occlusion of the arterial end-to-side anastomosis.

Indocyanine green angiography is a cheap alternative to 3-D CT angiography, which should be considered in selected cases. ICGA allows the pre- or intraoperative identification of perforators with a very high sensitivity, as demonstrated by experimental and clinical studies (Fig. 10) [32,33]. These studies compared ICG angiograms with the result of anatomic dissection and x-ray angiography. The range of measurements is up to 2 cm from the body surface, corresponding approximately to the level of the muscle fascia. The systemic administration of indocyanine green can be either intravenous or intraarterial, whereas the intraarterial injection seems to produce a better image contrast, probably because the concentration of ICG in the perforators increases faster after intraarterial injection [32] (Fig. 11).

SENTINEL NODE DETECTION

Sentinel lymph node mapping is used as a diagnostic method in order to increase staging accuracy without the well-known morbidities of radical lymphadenectomy. The sentinel node is defined as the first node to receive lymphatic drainage from a primary tumor. The sentinel node concept postulates that if the first draining node is negative for metastasis, the remaining lymph nodes in the nodal basin can be spared.

Sentinel lymph node (SLN) biopsy has become the most widely used procedure to determine the regional lymph node status of patients with skin cancer, breast cancer, and gastric cancer. The method of choice is the triple technique,

consisting of preoperative lymphoscintigraphy and intraoperative mapping with blue dye and a gamma probe.

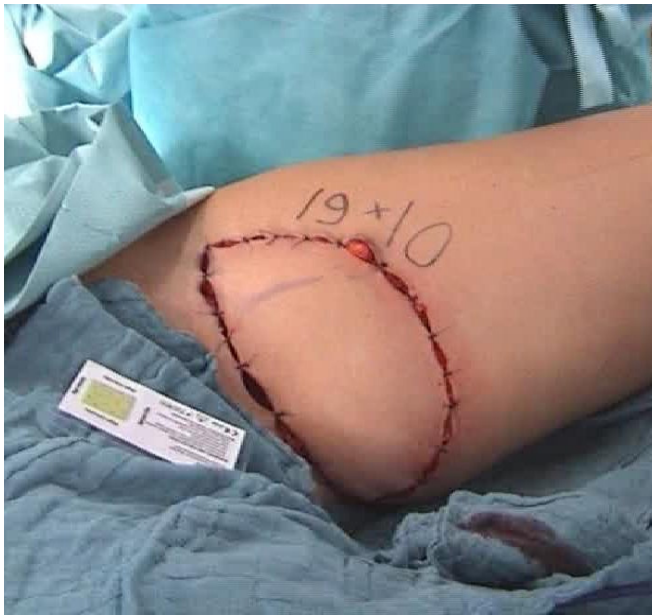

Fig. (10a). Free musculocutaneous gracilis flap after isolation on the vascular pedicle.

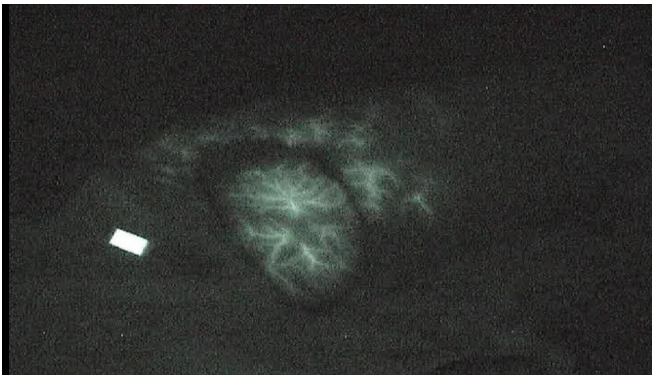

Fig. (10b). ICGA demonstrating 4 big perforating vessels from the medial circumflex femoral artery. Blood supply to the big skin island is excellent.

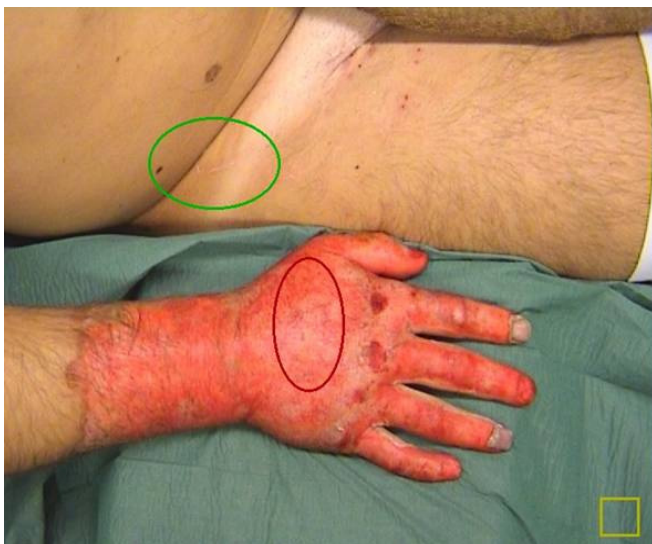
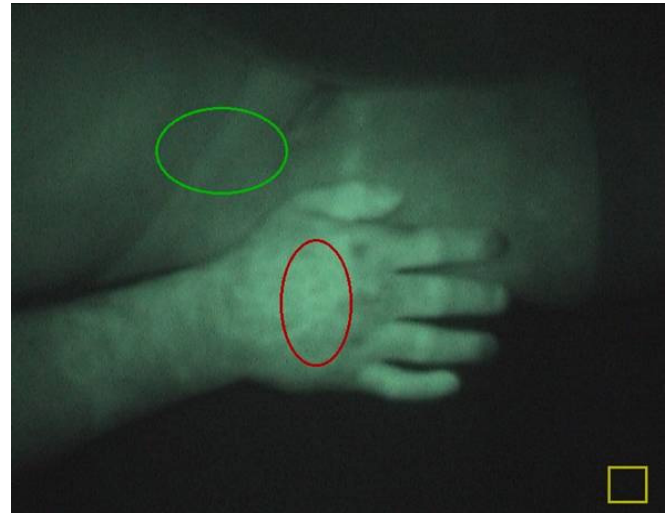
Fig. (11a). Burn of the right hand treated conservatively.

(b)



(c)

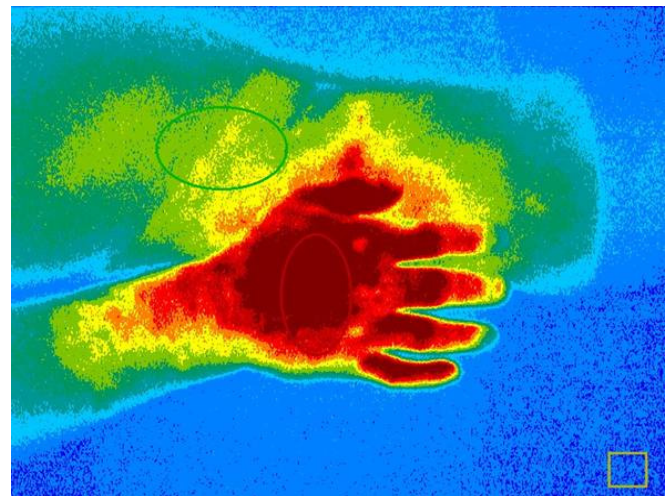


Fig. (11b, c). ICGA demonstrating a 1.6 fold increased perfusion index of the dorsum of the hand compared to healthy skin (green region). The burn was diagnosed as superficial dermal and healed spontaneously.

SLN detection using fluorescence navigation represents an alternative to the triple technique. It is based on the properties of indocyanine green, as ICG injected under the skin binds to albumin, and drains into the lymphatics without extravasation. When using the PDE near-infrared camera system, fluorescence images of subcutaneous lymphatic drainage can be obtained after ICG has been injected intradermally around the tumor. The sentinel node is identified with a large sensitivity, as shown by several clinical and experimental studies. Currently, SLN detection using fluorescence navigation has been described in patients with skin cancer, gastric cancer, breast cancer, and rectal cancer [34-36]. It is a promising novel technique, that combines the advantages of radioisotope and blue dye methods. Further clinical trials should provide useful perspectives on the future direction of fluorescence navigation surgery for sentinel node detection in cancer surgery.

BURN DEPTH ESTIMATION

Burn wound depth is a significant determinant of patient treatment and morbidity, and a rapid and accurate assessment of the burn wound is crucial in the treating burn-injured patients. Early burn eschar excision and skin grafting decreases mortality and is the standard of care in most institutions. Whereas superficial and very deep dermal burns are accurately identified by the burn surgeon, the differentiation between full-thickness from partial-thickness burns is often difficult, when based on clinical criteria alone. Overall estimates report that clinical depth assessment is accurate in about two third of the cases [37]. with the most frequent cause of error attributed to depth overestimation [38].

Several attempts have been undertaken to develop reliable technical means of burn depth assessment. Proposed modalities include punch biopsy, thermography, vital dyes, fluorescence, indocyanine green angiography, and laser doppler techniques [39]. When looking at all these modalities, laser doppler imaging and ICGA offer the best data-supported estimated of accuracy. Given that impaired microcirculation is directly associated with tissue necrosis, data from ICGA can determine dermal viability with high sensitivity. ICGA measurements early post burn have been shown to be significantly associated with the effective healing rate of the burn wound [40-42]. Most studies use normal unburned skin as a control to normalize measurements and the burn-to-normal tissue fluorescence ratio is considered a measure of burn wound depth.

Practical limitations of ICG angiography in burns include topical ointments, dressings, and blood, which decrease absorption and interfere with measurements [43]. This may lead to a dramatical overestimation of burn wound depth. Another limitation of ICG angiography is the capillary leak induced by the thermal injury, which might cause extravasation of the albumine-bound dye.

Although the scientific evidence for the use of ICGA in burn depth assessment seems adequate, it has never gained widespread use in the treatment of thermally injured patients. In most major burn centres, bedside clinical evaluation stays the most widely employed and cost-effective method. This is probably because clinical depth assessment can be performed immediately, easily, and without advanced instrumentation [39].

CONCLUSION

ICG fluorescence imaging provides simple and efficient intraoperative real-time angiographic imaging. The indications in the field of plastic and reconstructive surgery range from assessment of flap perfusion in pedicle and free flap surgery to patency assessment of microvascular anastomoses, sentinel node detection, lymph vessel identification, and burn depth estimation. Substantial evidence exists that intraoperative ICGA improves the quality of plastic surgical procedures and has the potential to reduce peri- and postoperative morbidity significantly. Based on the present data there is no doubt that routine implementation of intraoperative ICGA would represent a significant improvement in quality assurance.

REFERENCES

- [1] McGregor IA. Fundamental techniques of plastic surgery and their clinical surgical applications. USA: Churchill Livingstone 1980.
- [2] Krag C, Holck S. The value of the patency test in microvascular anastomosis: correlation between observed patency and size of intraluminal thrombus: an experimental study in rats. *Br J Plast Surg* 1981; 34: 64.
- [3] Raabe A, Nakaji P, Beck J, *et al.* Prospective evaluation of surgical microscope-integrated intraoperative near-infrared indocyanine green videoangiography during aneurysm surgery. *J Neurosurg* 2005; 103: 982.
- [4] Desai ND, Miwa S, Kodama D, *et al.* Improving the quality of coronary bypass surgery with intraoperative angiography: validation of a new technique. *J Am Coll Cardiol* 2005; 18: 1521.
- [5] Reuthebuch O, Häussler A, Genoni M, *et al.* Novadaq SPY: intraoperative quality assessment in off-pump coronary artery bypass grafting. *Chest* 2004; 25: 418.
- [6] Holm C, Melcer B, Hörbrand F, *et al.* Arterial thermodilution: An alternative to pulmonary artery catheter for cardiac output assessment in burn patients. *Burns* 2001; 27: 161-6.
- [7] Holm C, Mayr M, Tegeler J, *et al.* A clinical randomised study on the effects of invasive monitoring on burn shock resuscitation. *Burns* 2004; 30(8): 798-807.
- [8] Ishihara H, Otomo N, Suzuki A, *et al.* Detection of capillary protein leakage by glucose and indocyanine green dilutions during the early post-burn period. *Burns* 1998; 24: 525-31.
- [9] Speich R, Saselli B, Hoffmann U, Nefel KA, Reichen J. Anaphylactoid reactions after indocyanine green administration. *Ann Intern Med* 1988; 109: 345.
- [10] Flower RW, Hochheimer BF. Indocyanine green fluorescence and infrared absorption choroidal angiography performed simultaneously with fluorescein angiography. *Johns Hopkins Med J* 1976; 138: 33-42.
- [11] Cederna PS, Chang P, Pittet-Cuenod BM, *et al.* The effect of the delay phenomenon on the vascularity of rabbit rectus abdominis muscles. *Plast Reconstr Surg* 1997; 99: 194-205.
- [12] Sloan G, Sasaki S. Non-invasive monitoring of tissue viability. *Clin Plast Surg* 1985; 12: 185-95.
- [13] Still J, Law E, Dawson J, *et al.* Evaluation of the circulation of reconstructive flaps using laser-induced fluorescence of indocyanine green. *Ann Plast Surg* 1999; 42: 266-74.
- [14] Holm C, Mayr M, Höfter E, *et al.* Perioperative assessment of skin flap viability using laser-induced fluorescence of Indocyanine green. *Br J Plast Surg* 2002; 55: 635-44.
- [15] Holm C, Mayr M, Tegeler J, *et al.* Laser induced fluorescence of Indocyanine green: Plastic surgical applications. *Eur J Plast Surg* 2003; 26: 19-25.
- [16] Eren S, Rubben A, Krein R, *et al.* Assessment of microcirculation of an axial skin flap using Indocyanine green fluorescence angiography. *Plast Reconstr Surg* 1995; 96: 1636-49.
- [17] Matsui A, Lee BT, Winer JH, *et al.* Quantitative assessment of perfusion and vascular compromise in perforator flaps using a near-infrared fluorescence guided imaging system. *Plast Reconstr Surg* 2009; 124: 451-60.
- [18] Holzbach T, Taskov C, Henke J, *et al.* Evaluation of perfusion in skin flaps by laser-induced Indocyanine green fluorescence. *Handchir Mikrochir Plast Chir* 2005; 37(6): 396-402.
- [19] Giunta RE, Holzbach T, Taskov C, *et al.* Prediction of flap necrosis with laser induced indocyanine green fluorescence in a rat model. *Br J Plast Surg* 2005; 58(5): 695-701.
- [20] Matsui A, Lee BT, Winer JH, *et al.* Quantitative assessment of perfusion and vascular compromise in perforator flaps using a near-infrared fluorescence-guided imaging system. *Plast Reconstr Surg* 2009; 124(2): 451-60.
- [21] Mayr M, Holm C, Höfter E, *et al.* Effects of abdominoplasty on abdominal wall perfusion: A quantitative evaluation. *Plast Reconstr Surg* 2004; 114(6): 1586-94.
- [22] Holm C, Tegeler J, Mayr M, *et al.* Monitoring free flaps using laser-induced fluorescence of Indocyanine green. A preliminary experience. *Microsurgery* 2002; 22(7): 278-87.
- [23] Mothes H, Dönicke T, Friedel R, *et al.* Indocyanine-green fluorescence video angiography used clinically to evaluate tissue perfusion in microsurgery. *J Trauma* 2004; 57(5): 1018-24.
- [24] Mothes H, Dinkelaker T, Dönicke T, *et al.* Outcome prediction in microsurgery by quantitative evaluation of perfusion using ICG

- fluorescence angiography. *J Hand Surg Eur Vol* 2009; 34(2): 238-46.
- [25] Pestana IA, Coan B, Erdmann D, *et al.* Early experience with fluorescent angiography in free-tissue transfer reconstruction. *Plast Reconstr Surg* 2009; 123(4): 1239-44.
- [26] Holm C, Mayr M, Höfter E, Ninkovic M. Perfusion of the DIEP flap revisited: A clinical study. *Plast Reconstr Surg* 2006; 117(1): 37-43.
- [27] Holm C, Mayr M, Höfter E, *et al.* The versatility of the SIEA flap: A clinical assessment of the vascular territory of the superficial inferior epigastric artery. *J Plast Reconstr Aesthet Surg* 2007; 60: 946-51.
- [28] Holm C, Mayr M, Höfter E, *et al.* Inter-individual variability of the SIEA angiosome: impacts on operative strategies in breast reconstruction. *Plast Reconstr Surg* 2008; 122: 1612-20.
- [29] Holm C, Mayr M, Höfter E, *et al.* Assessment of the patency of microvascular anastomoses using microscope-integrated near-infrared angiography: a preliminary study. *Microsurgery* 2009; 29(7): 509-14.
- [30] Holm C, Dornseifer U, Sturtz G, *et al.* The intrinsic transit time of free microvascular flaps: Clinical and prognostic implications. *Microsurgery* 2010; 30(2): 91-6.
- [31] Uppal RS, Casaer B, Van Landuyt K, *et al.* The efficacy of preoperative mapping of perforators in reducing operative times and complications in perforator flap breast reconstruction. *J Plast Reconstr Aesthet Surg* 2009; 62(7): 859-64.
- [32] Azuma R, Morimoto Y, Masumoto K, *et al.* Detection of skin perforators by Indocyanine green fluorescence nearly infrared angiography. *Plast Reconstr Surg* 2008; 122(4): 1062-7.
- [33] Mausui A, Lee BT, Winer JH, *et al.* Image-guided perforator flap design using invisible near-infrared light and validation with X-ray angiography. *Ann Plast Surg* 2009; 63(3): 327-30.
- [34] Fujiwara M, Mizukami T, Suzuki A, *et al.* Sentinel lymph node detection in skin cancer patients using real-time fluorescence navigation with indocyanine green: preliminary experience. *J Plast Reconstr Aesthet Surg* 2009; 62(10): e373-8.
- [35] Murawa D, Hirche C, Dresel S, Hünnerbein M. Sentinel lymph node biopsy in breast cancer guided by indocyanine green fluorescence. *Br J Surg* 2009; 96(11): 1289-94.
- [36] Takahashi N, Nimura H, Fujita T, *et al.* Detection of sentinel node by fluorescence and infrared ray imaging system in gastric cancer. *Ann Surg Oncol* 2009; 16(6): 1720.
- [37] Heimbach DM, Afromowitz MA, Engrav LH, *et al.* Burn depth estimation – man or machine? *J Trauma* 1984; 24: 373-8.
- [38] Niazi ZB, Essex TJ, Papini R, *et al.* New laser Doppler scanner, a valuable adjunct in burn depth assessment. *Burns* 1993; 19: 485-9.
- [39] Devgan L, Bhat S, Asylward S, Spence RJ. Modalities for the assessment of burn wound depth. *J Burn Wounds* 2006; 5: e2.
- [40] Still JM, Law EJ, Klavuhn KG, *et al.* Diagnosis of burn depth using laser-induced Indocyanine green fluorescence: a preliminary clinical trial. *Burns* 2001; 27(4): 364-71.
- [41] Kamolz LP, Andel H, Haslik W, *et al.* Indocyanine green video angiographies help to identify burns requiring operation. *Burns* 2003; 29: 785-91.
- [42] Schomacker KT, Torri A, Sandison DR, *et al.* Biodistribution of Indocyanine green in a porcine burn model: light and fluorescence microscopy. *J Trauma* 1997; 43: 813-9.
- [42] Haslik W, Kamolz LP, Andel H, *et al.* The influence of dressings and ointments on the qualitative and quantitative evaluation of burn wounds by ICG video-angiography: an experimental set-up. *Burns* 2004; 30: 232-5.
- [43] Lehnhardt M, Jafari HJ, Druelcke D, *et al.* A qualitative and quantitative analysis of protein loss in human burn wounds. *Burns* 2005; 31(2): 159-67.

Received: December 1, 2009

Revised: December 23, 2009

Accepted: December 23, 2009

© Charlotte Holm; Licensee *Bentham Open*.

This is an open access article licensed under the terms of the Creative Commons Attribution Non-Commercial License (<http://creativecommons.org/licenses/by-nc/3.0/>) which permits unrestricted, non-commercial use, distribution and reproduction in any medium, provided the work is properly cited.