

# Breast Cancer

Yutaka Ogasawara<sup>\*,1</sup> and Hiroyoshi Doihara<sup>2</sup>

<sup>1</sup>Department of Surgery, Kagawa prefectural Central Hospital, Bancho, Takamatsu-City, Kagawa, Japan

<sup>2</sup>Department of Cancer and Thoracic Surgery, Okayama University Graduate School of Medicine, Dentistry and Pharmaceutical Sciences, Shikata-cho, Okayama-City, Okayama, Japan

**Abstract:** Recently, invisible near-infrared fluorescence imaging system (PDE) which can provide fluorescence imaging of lymphatic flow has been introduced in clinical areas for the therapy of breast cancer. This handy and portable instrument can provide a distinct image of subcutaneous lymphatic vessels in real-time. In sentinel lymph node biopsy (SLNB) using PDE, we can start SLNB at the optimum moment when the drainage lymphatic flow reaches to the axilla and identify the site of skin incision precisely. A satisfactory detection rate of the lymphatic drainage route and SLN was obtained using PDE. PDE has a potential as a modality to complement SLNB using a blue dye. On the other hand, PDE seems to be useful for the diagnosis and prediction of lymphedema after axillary dissection in patients with breast cancer because PDE could provide aberrant lymphatic structures in extremities with lymphedema.

## INTRODUCTION

Sentinel lymph node biopsy (SLNB) has been emerging as a minimally invasive alternative to axillary lymph node dissection for nodal staging in patient with breast cancer. SLN is defined as the first lymph node drained from the primary tumor. In SLNB, it is necessary to understand the breast lymphatic system enough. However, the breast lymphatic system has not been understood enough by the lack of lymphatic imaging methods, partly due to the poor contrast lymphatic fluids and structures. Study of the breast lymphatic system has increasingly been necessary for the therapy of breast cancer. Recently, invisible near-infrared fluorescence imaging system (PDE, Hamamatsu Photonics, Hamamatsu, Japan) which can provide fluorescence imaging of lymphatic flow has been introduced in clinical areas. This handy and portable instrument can provide a distinct image of subcutaneous lymphatic vessels in real-time. Hence, PDE seems to provide the surgeon with much useful information.

## BREAST LYMPHATIC SYSTEMS

Recently, using PDE, the breast lymphatic pathways were analyzed [1]. In this study, to obtain the fluorescence imaging of the breast, indocyanine green (ICG) was injected subdermally both in the subareolar site and in the site around the tumor (Fig. 1). In this report, in 33 (89.2%) of all, the drainage lymphatic pathway from the periareolar area was detected. Only 4 patients had no drainage lymphatic pathway from the periareolar area. Of these 4 patients, 2 patients had clinical positive nodes, one patient underwent neoadjuvant chemotherapy, and one patient was older (age>75years) and obese (BMI>30). These patients seemed to be detected no drainage lymphatic pathway unavoidably. In 33 patients with subdermal injection around the tumor, only 12(36.3%)

patients had the drainage lymphatic route from the peritumoral area. In brief, it is speculated that subdermal lymphatic vessels of the periareolar area is more abundant than other sites in the breast. Moreover, in 11(91.7%) patients of these 12 patients who had the drainage lymphatic route from the peritumoral area, the drainage lymphatic vessels from the periareolar area and the peritumoral area shared the same lymphatic vessels before directing to the axilla. Additionally, it was reported that the lymphatic pathway in the breast parenchyma flowed toward the subareolar lymphatic plexus and drained into the axilla [2-4]. From these reports, for SLNB using a blue dye, the subareolar injection appears to be more preferable than that in other sites.

CT – lymphography [3, 4] and lymphoscintigraphy [5] is often performed before SLNB. It shows drainage lymphatic route from the primary tumor to the axillary nodes. However, lymphoscintigraphy cannot clearly visualize the drainage lymphatic pathway because of the slow lymphatic migration, the limitation of spatial resolutions, and the lack of anatomic landmarks. Meanwhile, CT-lymphography can visualize the drainage lymphatic pathway clearly. However, ordinarily, CT requires expensive large equipment. Additionally, it cannot demonstrate in real-time. Meanwhile, PDE can visualize the drainage lymphatic pathway clearly in real-time in the operating room.

## FUNCTIONAL LYMPH IMAGING

Lymphedema is a common complication of axillary dissection in patients with breast cancer. This complication is associated with an inferior quality of life and a higher level of arm symptom-associated distress. However, its diagnostic strategies have not been established enough. Unno *et al.* identified several characteristics of fluorescent images in lymphedema subjects [6]. PDE could provide aberrant lymphatic structures in extremities with lymphedema. This technique may be useful to identify presence of lymphatic disorder. In another study, they performed quantitative

\*Address correspondence to this author at the Department of Surgery, Kagawa prefectural Central Hospital, 5-4-16 Bancho, Takamatsu-City, Kagawa, 760-8557, Japan; Tel: +81-87-835-2222; Fax: +81-87-834-8363; E-mail: yutaogasawa@kuh.biglobe.ne.jp

lymph imaging to measure transit times from the injection site [7]. Fluorescent imaging and dynamic lymphoscintigraphy was performed, and a strong correlation of transit times measured by the two methods was found. Lymphoscintigraphy is considered a major imaging modality for the diagnosis of patients with lymphedema and for evaluation of the swollen extremity. However, it is time consuming and expensive. Without a lymphoscintigram, lymphedema must be diagnosed purely from clinical criteria. However, at present, lymphedema can be diagnosed from the images of PDE. Moreover, lymphedema might be predicted from an aberrant image of lymphatic structures.

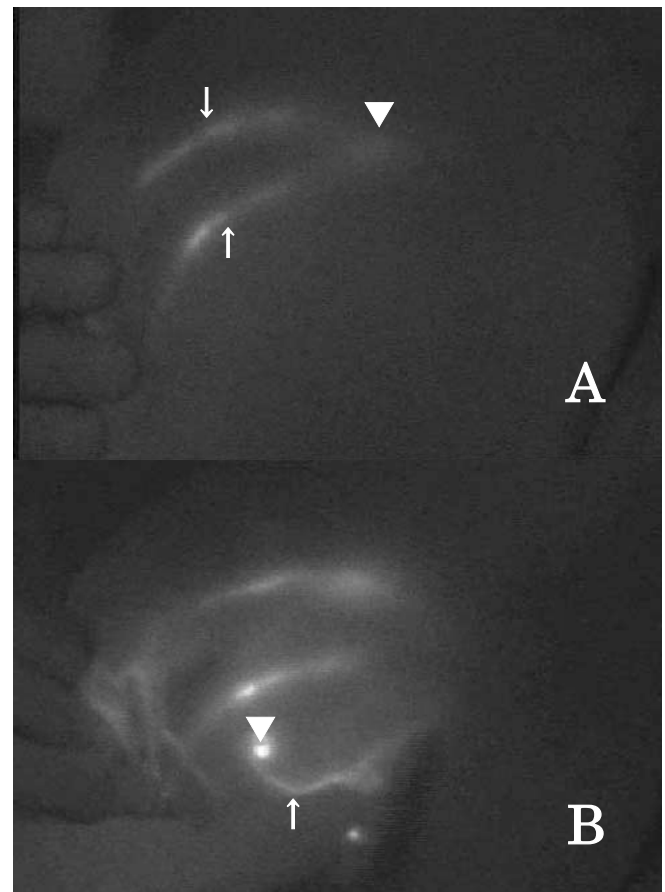
### SLNB USING PDE

The first use of PDE in SLNB was reported in Japan by Kitai *et al* [8]. In this study, 25 mg ICG in 5ml saline was injected in the subareolar breast tissue. In other studies, Tagaya *et al.* injected 1ml ICG (5mg) and 3ml indigo carmine dye subdermally in the areola [9], and we injected 15mg ICG in a total of 3ml of indigo carmine dye subdermally in the subareolar site and 10mg ICG in a total of 2ml of indigo carmine dye subdermally around the tumor [1]. 5~25mg ICG was used to obtain fluorescence imaging of the breast lymphatic flow using PDE (Table 1). However, in a recent study, it was reported that SLN mapping could be performed after administration of microdose amounts of ICG [10]. In this study, for eight of nine subjects receiving 10 $\mu$ g or more of ICG, draining lymphatic vessels were identified.

ICG is green and not apparent in the lymph node due to the color of the node. Meanwhile, indigo carmine dye is blue and more apparent in the lymph node than ICG. Accordingly, in SLNB, ICG which is diluted with indigo carmine dye seems to be more useful than ICG diluted with saline. And, the optimal location for injection of ICG appears to be the subareolar site as mentioned above.

Subcutaneous lymphatic pathways can be detected usually within one or two minutes after injection of ICG. In our study, the mean time to arrive at the axilla after subareolar injection was 88.7 seconds [1]. Additionally, significant correlation was seen between BMI and the time to arrive at the axilla after injection. In SLNB using PDE, we can visualize the drainage lymphatic route in real-time and start SLNB at the moment when the drainage lymphatic flow reaches to the axilla. Accordingly, a risk of labeling

non-SLN due to further migration of a tracer to subsequent distant nodes might be reduced.



**Fig. (1).** Indocyanine green fluorescence imaging. (A) After subareolar injection, two drainage lymphatic routes from the periareolar area was observed (arrow). These two lymphatic vessels shared the same lymphatic vessels before directing to the axilla (arrow head). (B) After subdermal injection around the tumor (arrow head), one drainage lymphatic route was observed from the peritumoral area (arrow).

The fluorescence line is observed in 1cm or less depth from the surface of the skin. The point where the fluorescence line disappeared near the axilla is regarded to be the point where the lymphatic routes drained from the subcutaneous tissue into the axillary space. In our study, the

**Table 1. Review of SLNB Using PDE**

Author, Year [Ref.]	No of Patients	Dosage	The Location for Injection of ICG	The Detection Rate of the Lymphatic Drainage Route	The Identified Rate of SLN	No of SLN (Range)
Kitai <i>et al.</i> , 2005 [8]	18	Unspecified amount of 5mg/ml ICG	Subareolar breast tissue	100%	94%	2.8 (1-6)
Tagaya <i>et al.</i> , 2008 [9]	25	5mg ICG and 3ml indigo carmine dye	Subcutaneous tissue of the areola	-----	100%	5.4 (3-10)
Ogasawara <i>et al.</i> , 2008 [1]	37	25mg ICG and 5ml indigo carmine dye	Subcutaneous tissue of the areola, subcutaneous tissue around the tumor	92%	-----	-----

Ref, references; No, number ; SLN, sentinel lymph node.

mean distance from the point between detected SLNs and the fluorescence line-disappeared point was 1.71cm [1].

The subcutaneous lymphatic lines were marked over the skin, and the skin incision was made at the point where SLNs seemed to be detected. After skin incision, the subcutaneous lymphatic lines were observed more clearly. Blue lymphatic channels were carefully dissected and traced until the first drained lymph node was detected. This lymph node was dissected carefully with the surrounding fatty tissue. When blue lymphatic channel was not detected clearly, PED was used for directional guidance. After SLNB, it was ensure if possible that no fluorescence spot was left in the axilla. All fluorescence lymph nodes were regarded as SLNs [8].

Subcutaneous lymphatic drainage route of the breast was observed by PDE in 92% and 100% patients, respectively [1, 8]. The identified rate of SLN was 94% and 100%, respectively [8, 9]. The number of SLNs was demonstrated at Table 1.

The advantage of SLNB using PDE are as follows;

- 1) The lymphatic routes can be detected in real time in the operating room.
- 2) The site of the skin incision can be defined precisely.
- 3) We can start SLNB at the moment when the drainage lymphatic flow reaches to the axilla.
- 4) PDE make it easy to recognize the lymphatic vessels and lymph nodes after skin incision.

However, this method has also some problems as follows;

- 1) A lymph vessel and node deep in the tissue cannot be visualized by PDE.
- 2) It is difficult to perform fluorescence navigation and lymphatic dissection simultaneously, since shadowless light in the operating room must be turned off during fluorescence navigation.

- 3) There is a time limitation for dissecting SLN because the injected ICG spreads easily through the subcutaneous tissue.

## CONCLUSIONS

Study of the breast lymphatic system is necessary for the therapy of breast cancer. PDE enables us to evaluate the lymphatic systems of the breast. PDE has a potential as a modality to complement SLNB using a blue dye. PDE seems to be useful for the diagnosis and therapy of lymphedema in patients with breast cancer.

## REFERENCES

- [1] Ogasawara Y, Ikeda H, Takahashi M, *et al.* Evaluation of breast lymphatic pathways with indocyanine green fluorescence imaging in patients with breast cancer. *World J Surg* 2008; 32: 1924-9.
- [2] Golshan M, Martin WJ, Dowlatshahi K. Sentinel lymph node biopsy lowers the rate of lymphedema when compared with standard axillary lymph node dissection. *Am Surg* 2003; 69: 209-11.
- [3] Suga K, Yuan Y, Okada M, *et al.* Breast sentinel lymph node mapping at CT lymphography with iopamidol: preliminary experience. *Radiology* 2004; 230: 543-52.
- [4] Tangoku A, Yamamoto S, Suga K, *et al.* Sentinel lymph node biopsy using computed tomography-lymphography in patients with breast cancer. *Surgery* 2004; 135: 258-65.
- [5] Ogasawara Y, Yoshitomi S, Sato S, *et al.* Clinical significance of preoperative lymphoscintigraphy for sentinel lymph node biopsy in breast cancer. *J Surg Res* 2008; 148: 191-6.
- [6] Unno N, Inuzuka K, Suzuki M, *et al.* Preliminary experience with a novel fluorescence lymphography using indocyanine green in patients with secondary lymphedema. *J Vasc Surg* 2008; 45: 1016-21.
- [7] Unno N, Nishiyama M, Suzuki M, *et al.* Quantitative lymph imaging for assessment of lymph function using indocyanine green fluorescence lymphography. *Eur J Vasc Endovasc Surg* 2008; 36: 230-6.
- [8] Kitai T, Inomoto T, Miwa M, *et al.* Fluorescence navigation with indocyanine green for detecting sentinel lymph nodes in breast cancer. *Breast Cancer* 2005; 12: 211-5.
- [9] Tagaya N, Yamazaki R, Nakagawa A, *et al.* Intraoperative identification of sentinel lymph nodes by near-infrared fluorescence imaging in patients with breast cancer. *Am J Surg* 2008; 195: 850-3.
- [10] Sevick-Muraca EM, Sharma R, Rasmussen JC, *et al.* Imaging of lymph flow in breast cancer patients after microdose administration of a near-infrared fluorophore: feasibility study. *Radiology* 2008; 246: 734-41.